



Original Article

Updated International Tuberous Sclerosis Complex Diagnostic Criteria and Surveillance and Management Recommendations



Hope Northrup, MD ^a, Mary E. Aronow, MD ^b, E. Martina Bebin, MD, MPA ^c, John Bissler, MD ^d, Thomas N. Darling, MD, PhD ^e, Petrus J. de Vries, MBChB, MRCPsych, PhD ^f, Michael D. Frost, MD ^g, Zoë Fuchs ^h, Elizabeth S. Gosnell, DMD, MS ⁱ, Nishant Gupta, MD ^j, Anna C. Jansen, MD, PhD ^k, Sergiusz Józwiak, MD, PhD ^l, J. Chris Kingswood, MSc ^m, Timothy K. Knilans, MD ⁿ, Francis X. McCormack, MD ^o, Ashley Pounders, MSN, FNP-C ^h, Steven L. Roberds, PhD ^h, David F. Rodriguez-Buritica, MD ^p, Jonathan Roth, MD ^q, Julian R. Sampson, DM ^r, Steven Sparagana, MD ^s, Elizabeth Anne Thiele, MD, PhD ^t, Howard L. Weiner, MD ^u, James W. Wheless, MD ^v, Alexander J. Towbin, MD ^w, Darcy A. Krueger, MD, PhD ^{x,*}, on behalf of the International Tuberous Sclerosis Complex Consensus Group[#]

^a Department of Pediatrics, McGovern Medical School, University of Texas Health Science Center at Houston, Houston, Texas

^b Retina Service, Massachusetts Eye and Ear, Harvard Medical School, Boston, Massachusetts

^c Department of Neurology, University of Alabama at Birmingham, Birmingham, Alabama

^d Department of Pediatrics, University of Tennessee Health Science Center and Le Bonheur Children's Hospital, Memphis, Tennessee

^e Uniformed Services University of the Health Sciences, Bethesda, Maryland

^f Division of Child and Adolescent Psychiatry, University of Cape Town, Cape Town, South Africa

^g Minnesota Epilepsy Group, St. Paul, Minnesota

^h TSC Alliance, Silver Spring, Maryland

ⁱ Department of Pediatrics, University of Cincinnati College of Medicine, and Division of Pediatric Dentistry, Cincinnati Children's Hospital Medical Center, Cincinnati, Ohio

^j Division of Pulmonary, Critical Care and Sleep Medicine, University of Cincinnati, Cincinnati, Ohio

^k Pediatric Neurology Unit, Department of Pediatrics, UZ Brussel, Neurogenetics Research Group, Vrije Universiteit Brussel, Brussels, Belgium

^l Department of Pediatric Neurology, Medical University of Warsaw, Warsaw, Poland

^m Cardiology Clinical Academic Group, Molecular and Clinical Sciences Research Centre, St Georges University of London, London, UK

ⁿ Cincinnati Children's Hospital Medical Center, University of Cincinnati College of Medicine, Cincinnati, Ohio

^o Division of Pulmonary, Critical Care and Sleep Medicine, University of Cincinnati, Cincinnati, Ohio

^p Division of Medical Genetics, Department of Pediatrics, McGovern Medical School, University of Texas at Houston Medical Center, Houston, Texas

^q Dana Children's Hospital, Tel Aviv Medical Center, Tel Aviv University, Israel

^r Institute of Medical Genetics, Division of Cancer and Genetics, Cardiff University Medical School, Cardiff, Wales, UK

^s Scottish Rite for Children and the University of Texas Southwestern Medical Center, Dallas, Texas

^t Department of Neurology, Massachusetts General Hospital, Boston, Massachusetts

^u Texas Children's Hospital, Baylor College of Medicine, Houston, Texas

^v Professor & Chief of Pediatric Neurology, Le Bonheur Chair in Pediatric Neurology, University of Tennessee Health Science Center; Director, Neuroscience Institute & Le Bonheur Comprehensive Epilepsy Program, Co-Director Le Bonheur Tuberous Sclerosis Center of Excellence, Le Bonheur Children's Hospital, Memphis, Tennessee

DOI of original article: <https://doi.org/10.1016/j.pediatrneurol.2021.07.010>.

* Communications should be addressed to: Dr. Krueger; Division of Neurology; Department of Pediatrics; Cincinnati Children's Hospital Medical Center; University of Cincinnati College of Medicine; 3333 Burnet Avenue; Cincinnati, OH 45229.

E-mail address: darcy.krueger@cchmc.org (D.A. Krueger).

[#] International Tuberous Sclerosis Complex Consensus Group: Nicholas M. P. Annear, Mary E. Aronow, Ute Bartels, E. Martina Bebin, Moncef Berhouma, John J. Bissler, Klemens Budde, Anna Byars, Harry Chugani, Edward W. Cowen, Peter B. Crino, Paolo Curatolo, Thomas N. Darling, Petrus de Vries, Daniel F. Dilling, David W. Dunn, Rosmary Ekong, Kevin C. Ess, David N. Franz, Michael Frost, Zoë D.B. Fuchs, Elizabeth Gosnell, Lisa Guay-Woodford, Nishant Gupta, Luciana Haddad, Anne Halbert, Adelaide A. Hebert, Elizabeth P. Henske, Gregory L. Holmes, Dena Hook, John Hulbert, Anna Jansen, Simon R. Johnson, Sergiusz Józwiak, Bryan King, J. Christopher Kingswood, Timothy K. Knilans, Mary Kay Koenig, Bruce Korf, Darcy A. Krueger, David J. Kwiatkowski, Francis X. McCormack, Joel Moss, David Mowat, Kate Mowrey, Rima Nabbout, Mark D. Nellist, Hope Northrup, Finbar O'Callaghan, Uday Patel, Ashley Pounders, E. Steve Roach, Steven L. Roberds, David Rodriguez-Buritica, Robb Romp, Jonathan Roth, Micaela Rozenberg, Stephen J. Ruoss, Mustafa Sahin, Julian Sampson, Joshua A. Samuels, Matthias Sauter, Catherine A. Smith, Keyomars Soltani, Steven Sparagana, Shoba Srivastava, Clare Stuart, Joyce M. C. Teng, Elizabeth A. Thiele, Alexander J. Towbin, Andrew Trout, Agnies van Eeghen, Stephanie Vanclooster, Henry Z. Wang, Mari Wataya-Kaneda, Howard L. Weiner, James W. Wheless, Patricia Witman, Tim Wright, Joyce Y. Wu, Lisa Young.

<https://doi.org/10.1016/j.pediatrneurol.2021.07.011>

0887-8994/© 2021 The Authors. Published by Elsevier Inc. This is an open access article under the CC BY-NC-ND license (<http://creativecommons.org/licenses/by-nc-nd/4.0/>).

^w Cincinnati Children's Hospital, Department of Radiology, University of Cincinnati College of Medicine, Cincinnati, Ohio^x Division of Neurology, Cincinnati Children's Hospital Medical Center, Department of Pediatrics, University of Cincinnati College of Medicine, Cincinnati, Ohio

ARTICLE INFO

Article history:

Received 13 July 2021

Accepted 20 July 2021

Available online 24 July 2021

Keywords:

Tuberous sclerosis complex (TSC)

Diagnostic criteria

Surveillance and management guidelines

Practical guidance

ABSTRACT

Background: Tuberous sclerosis complex (TSC) is an autosomal dominant genetic disease affecting multiple body systems with wide variability in presentation. In 2013, *Pediatric Neurology* published articles outlining updated diagnostic criteria and recommendations for surveillance and management of disease manifestations. Advances in knowledge and approvals of new therapies necessitated a revision of those criteria and recommendations.

Methods: Chairs and working group cochairs from the 2012 International TSC Consensus Group were invited to meet face-to-face over two days at the 2018 World TSC Conference on July 25 and 26 in Dallas, TX, USA. Before the meeting, working group cochairs worked with group members via e-mail and telephone to (1) review TSC literature since the 2013 publication, (2) confirm or amend prior recommendations, and (3) provide new recommendations as required.

Results: Only two changes were made to clinical diagnostic criteria reported in 2013: "multiple cortical tubers and/or radial migration lines" replaced the more general term "cortical dysplasias," and sclerotic bone lesions were reinstated as a minor criterion. Genetic diagnostic criteria were reaffirmed, including highlighting recent findings that some individuals with TSC are genetically mosaic for variants in *TSC1* or *TSC2*. Changes to surveillance and management criteria largely reflected increased emphasis on early screening for electroencephalographic abnormalities, enhanced surveillance and management of TSC-associated neuropsychiatric disorders, and new medication approvals.

Conclusions: Updated TSC diagnostic criteria and surveillance and management recommendations presented here should provide an improved framework for optimal care of those living with TSC and their families.

© 2021 The Authors. Published by Elsevier Inc. This is an open access article under the CC BY-NC-ND license (<http://creativecommons.org/licenses/by-nc-nd/4.0/>).

Introduction

Tuberous sclerosis complex (TSC) is a rare genetic disorder that can affect any organ system.¹ Many manifestations can be associated with severe morbidity and potentially death, so early diagnosis and appropriate lifelong surveillance and management are crucial. Given that the clinical manifestations of TSC are varied in age of onset and the extent of systemic involvement and severity, TSC clinical features may present dynamically over the course of an individual's life.² The incidence of TSC has been estimated many times and generally falls between 1:6000 and 1:10,000 live births. A comprehensive study in the United Kingdom estimated the incidence at 1:5800 live births,³ and a more recent study in Germany using the most recent diagnostic criteria⁴ estimated the incidence rate from 1:6760 to 1:13,520 live births.⁵

Major updates to clinical consensus guidelines for the diagnosis, surveillance, and management of TSC were published in 1998,⁶ 1999,⁷ and 2013.^{4,8} Recognizing that many new clinical studies and important new drug approvals had occurred or were pending, chairs and cochairs of working groups involved in the 2012 TSC Clinical Consensus Conference met over two days at the 2018 World TSC Conference organized by the TSC Alliance in collaboration with TSC International (TSCi). Each disease area of TSC was reviewed by its respective working group to identify which recommendations were significantly impacted by advances in understanding TSC pathogenesis and clinical treatment since 2012. Only minor updates were recommended to the diagnostic criteria, but several important changes were recommended to surveillance and management criteria, primarily reflecting increased understanding of TSC-associated neuropsychiatric disorders (TAND) and newly approved medications for epilepsy in TSC with novel mechanisms of action. Over the next two years, the relevant working groups were tasked with drafting new recommendations for each of these areas. In addition, all working groups of the International TSC

Consensus Group were asked to review and affirm recommendations to be continued from 2012, providing additional clarity or emphasis when necessary to address unintended ambiguity or unanticipated obstacles to implementation that had since emerged. Working group deliberations and drafting of updated recommendations continued between 2018 and 2021, culminating in the current document. The result of these efforts is reported here as current consensus guidelines for the diagnosis, surveillance, and management of TSC.

Methods

Updating these guidelines employed the structure and methods as described for the previous update^{4,8} with two exceptions. First, additional experts were consulted either to replace participants in the previous update who were no longer available or to supplement expertise. Second, only 24 individuals, including the chairs and working group cochairs, met in person during the 2018 World TSC Conference in Dallas, TX, USA, because updates did not need to be as extensive as the changes between 1998 and 2013. Over the next two years, working group cochairs engaged their working group members to review relevant literature and draft an update to their working group's recommendations.

A comprehensive literature search was performed on May 10, 2018, to prepare for discussions on July 25 and 26, 2018. This search used the same terms as the previous update^{4,8} from 2012 through 2018. Additional literature searches addressing key questions not included by (or more recent than) the general search were performed as needed by each individual working group.

To assess the strength of evidence and resulting recommendations, the same National Comprehensive Cancer Network Clinical Guidelines framework⁹ was used as before⁸ (Table 1).

These 2021 International Tuberous Sclerosis Complex Consensus Group surveillance and management recommendations

TABLE 1.
Recommendation Categories and Descriptions

Category	Description	Supporting Evidence
1	Based upon high-level evidence, there is uniform consensus that the intervention is appropriate	At least one convincing class I study OR at least two convincing and consistent class II studies OR at least three convincing and consistent class III studies
2A	Based upon lower-level evidence, there is uniform consensus that the intervention is appropriate	At least one convincing class II study OR at least two convincing and consistent class III studies
2B	Based upon lower-level evidence, there is consensus that the intervention is appropriate	At least one convincing class III study OR at least two convincing and consistent class IV studies
3	Based upon any level of evidence, a consensus on appropriate intervention cannot be reached	Class I-IV studies that are conflicting or inadequate to form a consensus

Class definitions for supporting evidence:

Class I: evidence provided by a prospective, randomized controlled clinical trial with masked outcome assessment, in a representative population.

Class II: evidence provided by a prospective matched group cohort study in a representative population with masked outcome assessment.

Class III: evidence provided by all other controlled trials (including well-defined natural history controls or patients serving as own controls) in a representative population, where outcome assessment is independent of patient treatment.

Class IV: evidence provided by uncontrolled studies, case series, case reports, or expert opinion.

are organized into two sections: (1) recommendations applicable at the time of initial diagnoses and (2) recommendations for ongoing health care. There is some overlap with this approach because certain features discovered upon initial diagnosis may require immediate intervention, additional evaluation, or specialist referral. By necessity, discussion in this article is limited to the most relevant and updated points that differ or have evolved since 2013.

Diagnostic criteria update

Genetic diagnostic criteria

The International TSC Clinical Consensus Group reaffirms the importance of independent genetic diagnostic criteria and clinical diagnostic criteria.⁴ Identification of a pathogenic variant in *TSC1* or *TSC2* is sufficient for the diagnosis or prediction of TSC regardless of clinical findings; this is important because manifestations of TSC are known to arise over time at various ages.^{10,11} Genetic diagnosis of TSC prior to an individual meeting clinical criteria for TSC is beneficial to ensure that individuals undergo necessary surveillance to identify manifestations of TSC as early as possible to enable optimal clinical outcomes.

Determination of pathogenicity of genetic variants of *TSC1* or *TSC2* should follow standards and guidelines of the American College of Medical Genetics (ACMG) for interpretation of sequence variants,¹² now widely adopted as the international standard. Broadly, a “pathogenic” variant is one that clearly prevents protein synthesis and/or inactivates the function of the *TSC1* or *TSC2* proteins (e.g., nonsense or frameshift variants, large genomic deletions) or is a missense variant whose effect on protein function has been established by functional assessment.^{13–16} *TSC1* and *TSC2* variants whose effect on protein synthesis or function is less certain are not definitely pathogenic and would not be considered diagnostic unless supported by additional ACMG criteria for pathogenicity.¹² Many pathogenic variants identified to date have been carefully curated (www.lovd.nl/TSC1, www.lovd.nl/TSC2), but it should be noted that novel pathogenic variants in *TSC1* or *TSC2* continue to be identified as genetic testing is increasingly accessible and utilized. If the pathogenic variant in an affected relative is known, targeted testing for known familial variants has very high predictive value for family members.

Between 10% and 15% of patients with TSC meeting clinical diagnostic criteria have no mutation identified by conventional genetic testing.¹⁷ Therefore, failure to identify a pathogenic variant in *TSC1* or *TSC2* does not exclude a diagnosis of TSC.

High-read-depth approaches in next-generation sequencing (NGS) demonstrate low-level mosaic pathogenic variants in some individuals with clinical signs of TSC in whom standard NGS or pre-NGS testing proved normal.¹⁷ Intronic splice site mutations are also important to identify as a potential cause for TSC.¹⁷ Although mosaic individuals may experience fewer findings of TSC, they may develop any manifestation of TSC and are at risk to have offspring who are nonmosaic for TSC,¹⁸ so diligent surveillance and genetic counseling are warranted.¹⁹

Clinical diagnostic criteria

The clinical diagnostic criteria as established at the 2012 Consensus Conference⁴ were reviewed by each working group, who then recommended whether to keep, change, add, or delete specific major or minor criteria. The new diagnostic clinical criteria have only two changes from the previous version and now include 11 major features and seven minor features (Table 2). The previous major clinical diagnostic criterion of “cortical dysplasias” was found to be too nonspecific in practice and potentially confusing to clinicians, given that TSC is one of several causes of focal cortical dysplasias. The new criterion is “multiple cortical tubers and/or radial migration lines,” which is more specific to TSC.

The dermatology and dental working group recommended adding back the minor clinical diagnostic criteria “sclerotic bone lesions.” Sclerotic bone cysts had been eliminated in 2012 as a minor clinical criterion. However, in the intervening years, working group members observed heightened and unwarranted concern among some medical care providers about the possibility of metastatic cancer. Sclerotic bone lesions are commonly observed in individuals with TSC when high-resolution chest computed tomography (CT) is performed as surveillance for possible lymphangiomyomatosis (LAM) or abdominal magnetic resonance imaging (MRI) is performed as surveillance for renal angiomyolipoma.^{20,21} These bone lesions are common and relatively specific for TSC.²² It is important that clinicians understand that these lesions are not surprising in TSC and rarely require intervention, and they should not raise undue alarm of possible cancer.

Surveillance and management recommendations for individuals with newly suspected or newly diagnosed TSC

Recommendations are summarized in Table 3. The strength of each of the following recommendations is Category 3 unless specified otherwise.

TABLE 2.
Diagnostic Criteria

Major Criteria	Minor Criteria
Hypomelanotic macules (≥3; at least 5 mm diameter)	“Confetti” skin lesions
Angiofibroma (≥3) or fibrous cephalic plaque	Dental enamel pits (≥3)
Ungual fibromas (≥2)	Intraoral fibromas (≥2)
Shagreen patch	Retinal achromic patch
Multiple retinal hamartomas	Multiple renal cysts
Multiple cortical tubers and/or radial migration lines	Nonrenal hamartomas
Subependymal nodule (≥2)	Sclerotic bone lesions
Subependymal giant cell astrocytoma	
Cardiac rhabdomyoma	
LAM*	
Angiomyolipomas (≥2)*	

Abbreviations:

LAM = Lymphangiomyomatosis

TSC = Tuberous sclerosis complex

Definite TSC: 2 major features or 1 major feature with 2 minor features.

Possible TSC: either 1 major feature or ≥2 minor features.

Genetic diagnosis: A pathogenic variant in *TSC1* or *TSC2* is diagnostic for TSC (most TSC-causing variants are sequence variants that clearly prevent *TSC1* or *TSC2* protein production. Some variants compatible with protein production [e.g., some missense changes] are well established as disease-causing; other variant types should be considered with caution).

* A combination of the 2 major clinical features LAM and angiomyolipomas without other features does not meet criteria for a definite diagnosis.

TABLE 3.
Surveillance and Management Recommendations for Newly Diagnosed or Suspected TSC

Organ System or Specialty Area	Recommendations
Genetics	Obtain three-generation family history to assess for additional family members at risk of TSC. Offer genetic testing for family counseling or when TSC diagnosis is in question but cannot be clinically confirmed.
Brain	Obtain MRI of the brain to assess for the presence of tubers, SEN, migrational defects, and SEGA. During infancy, educate parents to recognize infantile spasms and focal seizures, even if none have occurred at the time of first diagnosis. Obtain baseline routine EEG while awake and asleep. If abnormal, especially if features of TAND are also present, follow-up with 8- to 24-h video-EEG to assess for seizure activity.
TAND	Perform comprehensive assessment for all levels of potential TAND manifestations (see Fig of TAND umbrella for details of levels). Refer as appropriate to suitable professionals to initiate evidence-based interventions based on the TAND profile of above-identified needs. Provide parent/caregiver education and training about TAND to ensure families know what to look out for in emerging TAND manifestations (e.g. autism spectrum disorder, language disorders, attention-deficit/hyperactivity disorder, anxiety disorders). Provide psychological and social support to families around diagnosis, coming to terms with the diagnosis of TSC and TAND, and ensure strategies are in place to support caregiver well-being.
Kidney	Obtain MRI of the abdomen to assess for the presence of angiomyolipomas and renal cysts. Screen for hypertension by obtaining an accurate blood pressure. Evaluate renal function by determination of GFR.
Lung	Inquire about tobacco exposure, connective tissue disease manifestations, signs of chyle leak, and pulmonary manifestations of dyspnea, cough, and spontaneous pneumothorax in all adult patients with TSC. Perform baseline chest CT in all females, and symptomatic males, starting at age 18 years or older. Perform baseline PFTs and 6MWT in patients with evidence of cystic lung disease consistent with LAM on the screening chest CT.
Skin	Perform a detailed clinical dermatologic inspection/examination.
Teeth	Perform a detailed clinical dental inspection/examination.
Heart	Consider fetal echocardiography to detect individuals with high risk of heart failure after delivery when rhabdomyomas are identified via prenatal ultrasound. Obtain an echocardiography in pediatric patients, especially if younger than age three years.
Eye	Obtain an electrocardiography at all ages to assess for underlying conduction defects. Perform a complete ophthalmologic evaluation, including dilated fundoscopy, to assess for retinal findings (astrocytic hamartoma and achromic patch) and visual field deficits.

Abbreviations:

6MWT = 6-Minute walk test

CT = Computed tomography

EEG = Electroencephalography

GFR = Glomerular filtration rate

LAM = Lymphangiomyomatosis

MRI = Magnetic resonance imaging

PFT = Pulmonary function test

SEGA = Subependymal giant cell astrocytoma

SEN = Subependymal nodules

TAND = TSC-associated neuropsychiatric disorder

TSC = Tuberous sclerosis complex

Genetics

All individuals should have a three-generation family history obtained to determine if additional family members are at risk of the condition. Genetic testing is recommended for genetic counseling purposes or when the diagnosis of TSC is suspected or in question but cannot be clinically confirmed (Category 1).

Brain

All individuals suspected of having TSC, regardless of age, should undergo MRI of the brain to assess for the presence of cortical or subcortical tubers, other types of neuronal migration defects, subependymal nodules, and subependymal giant cell astrocytomas (SEGAs). If MRI is not available or cannot be performed, CT or head ultrasound (in neonates or infants when fontanels are open) may be used, although these frequently will not detect all abnormalities revealed by MRI^{23,24} (Category 1).

Recently, gadolinium deposition in the brain has drawn attention,²⁵ although newer macrocyclic gadolinium agents lower the risk of depositions compared with older linear gadolinium agents^{26,27} and the long-term clinical implications are unknown.^{25,28} Although gadolinium can be used to better demonstrate SEGAs, in light of the need for repeated scans during childhood and potential side effects of contrast agents, combined

with noncontrast imaging sequences generally sufficient for screening for SEGA, we recommend avoiding contrast agents until there is a growing lesion or clinical suspicion of SEGA. In the latter circumstances, gadolinium can better define the lesion size, characteristics, and margins and nearby anatomical structures, which may be important for decision-making and for planning and monitoring treatment response.

Focal seizures and epileptic spasms occur in most (63% to 78%) infants with TSC, and caregivers should be educated to recognize these even if none are reported at the time of diagnosis.¹⁰ A helpful resource is the Infantile Spasms Action Network (<https://infantilespasms.org/what-can-is-look-like/>). Also, at the time of diagnosis, children with TSC should undergo routine baseline electroencephalography (EEG), prolonged if necessary to include both awake and sleep stages, even if patient has never reported clinical seizures or epileptic spasms previously. If epileptic spasms or focal seizures are suspected but cannot be confirmed clinically or the baseline EEG reveals abnormalities that are nonspecific, the patient should have an eight- to 24-hour video-EEG that includes sleep, which may detect electrographic seizures or interictal epileptiform discharges that have been shown to be strongly predictive of impending epilepsy.^{29,30} Early recognition and control of seizures is highly correlated with improved developmental and neurological outcomes,^{31–33} and pre-emptive treatment with vigabatrin before the onset of clinical seizures may provide additional benefit of preventing or delaying seizure onset in at-risk infants diagnosed with TSC and epileptiform activity on EEG.³⁴ However, pre-emptive treatment with vigabatrin may not be able to improve developmental and neurological outcomes over that achieved by early recognition and control of clinical seizures alone^{34,35} (Category 2A).

Children with TSC should be referred initially to a pediatric neurologist with expertise in epilepsy associated with TSC. Likewise, adults with TSC should be evaluated by an adult neurologist with expertise in epilepsy associated with TSC. Ongoing management may then be coordinated with a general pediatrician or general neurologist if preferred or necessary (e.g., in regions or countries with limited availability or access to epilepsy or TSC specialists).

TSC-associated neuropsychiatric disorders (TAND)

The term, “TAND,” and related terminology was introduced in 2013⁸ and readily accepted as an umbrella term encompassing interrelated neuropsychiatric manifestations common in TSC, including behavioral, psychiatric, intellectual, academic, neuropsychological, and psychosocial difficulties and disorders (Fig). TAND issues are common and are often the most impactful aspect of TSC, yet they are least likely to be addressed and controlled by existing treatments.³⁶ The TAND Checklist (lifetime version, TAND-L) was developed in 2015^{37,38} as a screening tool to identify neuropsychiatric concerns in a person of any age by encouraging and guiding conversations between individuals or caregivers and a health care provider. The TAND Checklist is freely available and can be downloaded in 19 languages (<https://tandconsortium.org/checklists/>).

At diagnosis, all patients should receive comprehensive assessment for TAND manifestations to identify areas needing immediate or early intervention³⁷ (Category 1). Patients should be referred as appropriate to suitable professionals to initiate evidence-based interventions for any difficulties or disorders identified (Category 1), and parents or caregivers of children and dependent adults should be educated about TAND to ensure that families know what to look for as potential emerging TAND manifestations^{37,39} (Category 2A). Family members may also need psychological and social

support while coming to terms with the diagnosis of TSC and TAND, so strategies should be in place to support caregiver well-being^{40,41} (Category 2B).

Kidney

At the time of diagnosis, abdominal imaging should be obtained regardless of age. MRI is the preferred modality for the evaluation of angiomyolipoma because 25% to 30% can be fat poor⁴² and may be missed when abdominal ultrasonography is performed.⁴³ In the event MRI is not possible an abdominal CT would be the next preferred modality. Intravenous contrast can help with identification of renal cysts and lipid-poor angiomyolipoma on abdominal CT and is likely less harmful than previously feared,⁴⁴ especially in patients with normal renal function (glomerular filtration rate [GFR] >60 mL/min/1.73 m²).^{45,46}

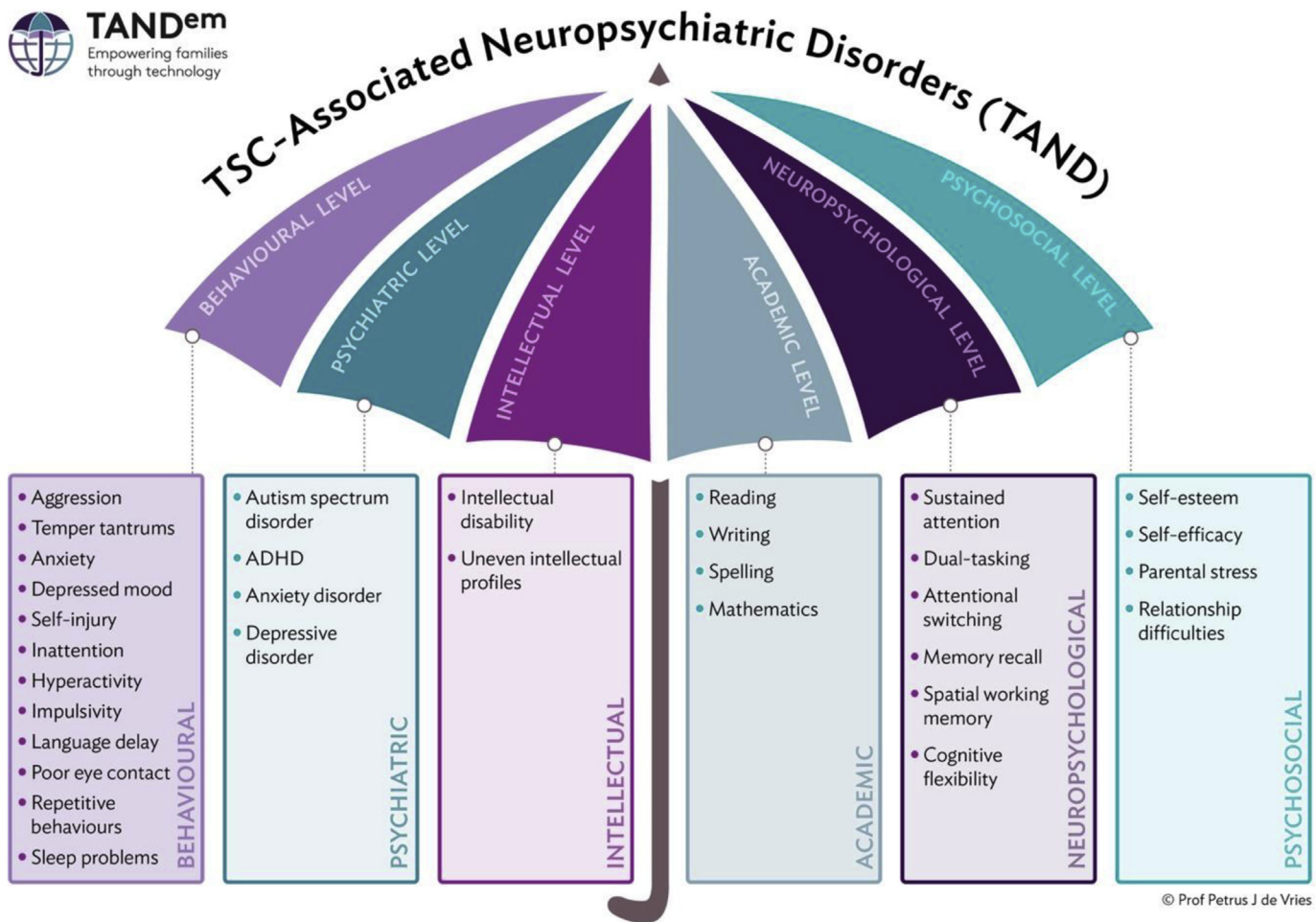
MRI of the brain and abdomen can be coordinated, thereby limiting the need for multiple sessions of anesthesia if needed for successful MRI. MRI of the abdomen may also reveal aortic aneurysms or extrarenal hamartomas of the liver and neuroendocrine tumors in the pancreas and other abdominal organs that also can occur in individuals with TSC.⁴⁷ In addition to imaging, accurate blood pressure assessment is important because of the increased risk of secondary hypertension.^{48,49} To assess kidney function at time of diagnosis, blood tests should be obtained to determine GFR using creatinine or cystatin C equations for adults^{50,51} or children.^{52,53} Patients with reduced muscle mass for any reason, including significant developmental delays, can have artifactually increased estimated GFR if a creatinine equation is used. In such situations, measurement of serum cystatin C concentration can be used to more accurately evaluate GFR^{52,54} (Category 1).

Lung

Clinical assessment for LAM and chest CT should be performed in all females, and symptomatic males, 18 years or older. Ultra-low-dose CT acquisition protocols are recommended when possible to limit radiation exposure.⁵⁵ High-resolution CT (HRCT) is not needed to diagnose cysts that are characteristic of LAM but can be useful for the differentiation of dependent abnormalities such as pleural/chylous effusions or dependent atelectasis.⁵⁶ Minimum intensity projection-reformatted images⁵⁷ also can be used to better identify extremely small cysts.

Key elements of history include information about family history of lung diseases, occupational and environmental exposures, tobacco use, features of connective tissue diseases, dyspnea on exertion, cough, hemoptysis, chest pain, and history of pneumothorax. Baseline pulmonary function tests (PFTs) including pre-bronchodilator spirometry and postbronchodilator spirometry, lung volumes, and diffusion capacity of the lung for carbon monoxide, and six-minute walk test should be performed in individuals with lung cysts consistent with LAM on the screening CT. Although in cross-sectional studies serum vascular endothelial growth factor-D (VEGF-D) has excellent positive and moderate negative predictive value for the presence of LAM in women with TSC,^{58–60} it has not been tested prospectively as a screening tool to signal the need for a CT and cannot yet be routinely recommended for that purpose (Category 2A).

Multifocal micronodular pneumocyte hyperplasia (MMPH) refers to benign, nodular proliferation of type II pneumocytes that occurs in both men and women with TSC.⁶¹ Radiologically, MMPH appears as multiple, often diffusely distributed, discrete solid and ground glass nodules, typically ranging between 2 and 14 mm in diameter, with no consistent central/peripheral or apical/basilar distribution.⁶² Given that MMPH has rarely been reported in



© Prof Petrus J de Vries

FIGURE. Spectrum of tuberous sclerosis complex (TSC)-associated neuropsychiatric disorder (TAND) levels and features in TSC. Courtesy of Petrus de Vries, Anna Jansen, and Stephanie Vanclooster on behalf of the International TAND Consortium (<https://tandconsortium.org/about/>). The color version of this figure is available in the online edition.

patients with sporadic LAM, and that non-MMPH nodules are often radiologically indistinguishable from MMPH, the panel recommends that a radiological diagnosis of MMPH should not be a diagnostic criterion for TSC. A lung biopsy of nodules for the purpose of establishing the diagnosis of TSC is not recommended.

Skin

Comprehensive dermatologic evaluation by an experienced specialist is recommended at the time of diagnosis for all patients. Wood's lamp is helpful in detecting hypomelanotic macules. Anticipatory guidance regarding expectations and potential treatments is advised. Sun protection is recommended, for both adults and children, considering the photosensitivity of hypomelanotic macules and the presence of mutations consistent with those induced by ultraviolet radiation in angiofibromas.⁶³ Intervention with mechanistic target of rapamycin (mTOR) inhibitors (mTORis), pulsed-dye or ablative lasers, or surgical excision can be appropriate for large or disfiguring lesions and for lesions prone to bleeding or a source of pain.⁶⁴

Teeth

For newly diagnosed infants, baseline oral evaluation and establishment of a primary dental care provider is recommended at

the time of the eruption of the first tooth or no later than age 12 months. If an oral evaluation has not been completed, a baseline evaluation is recommended at the time of diagnosis. A simple technique of utilizing dental disclosing solution can assist the practitioner in delineating the enamel pits more effectively.⁶⁵⁻⁶⁷ Solitary lesions (intraoral fibroma or enamel pit) may occur in the general population. If the practitioner identifies multiple lesions, however, it would be prudent to screen for other TSC-related findings (Category 2B).

Heart

All individuals should have age-appropriate cardiac evaluation at the time of diagnosis.⁶⁸ In pediatric patients, especially younger than age three years, an echocardiography and a 12- to 15-lead electrocardiography (ECG) should be obtained to evaluate for rhabdomyomas and arrhythmias, respectively. In those individuals with rhabdomyomas identified via prenatal ultrasound, fetal echocardiography may be useful to detect those individuals with high risk of heart failure after delivery (Category 1).

In the absence of cardiac symptoms or concerning medical history, echocardiography is not necessary in adults, but as conduction defects may still be present and may influence medication choice and dosing,⁶⁸ a baseline ECG is still recommended (Category 2A).

Eye

A baseline ophthalmologic evaluation, including dilated fundoscopic evaluation, is recommended for all individuals diagnosed with TSC to screen for retinal astrocytic hamartomas and retinal achromic patches. Retinal astrocytic hamartomas are observed in 30% to 50% of patients with TSC, are bilateral in 43% of cases, and multiple in 40%. These lesions are located most frequently in the posterior pole, along the vascular arcades, and adjacent to the optic nerve⁶⁹ (Category 1).

Other

Although aneurysms, gastrointestinal polyps, bone cysts, and various endocrinopathies can be associated with TSC,^{20,70} there is insufficient evidence to support routine evaluation at the time of diagnosis unless there are clinical symptoms or other concerning history that warrants specific investigation.

Ongoing surveillance and management recommendations for individuals previously diagnosed with TSC

Recommendations are summarized in Table 4. The strength of each of the following recommendations is Category 3 unless otherwise specified.

Genetics

Genetic testing and counseling should be offered to individuals with TSC and first-degree relatives where this has not been done previously. All affected individuals should be offered clinical assessment and genetic testing in the form of a *TSC1* and *TSC2* panel. When a pathogenic variant has been identified in the index case, genetic testing should be offered to at least the first-degree relatives (Category 1).

Subependymal giant cell astrocytoma (SEGA)

Individuals with SEGAs presenting with acute deterioration due to obstructive hydrocephalus, or tumoral hemorrhage, should undergo urgent surgical treatment. Minimally invasive surgical techniques are becoming available and may increase surgical safety in selected patients. Endoscopic resections are applicable to relatively small lesions, but are not widely used.^{71–73} Laser interstitial thermal therapy has been described in case reports, but long-term results are lacking.^{74,75} Early treatment is recommended, and experienced surgical teams are a prerequisite for balanced decision-making and reduced patient morbidity and mortality.^{72,76,77} For large tumors, treatment of hydrocephalus with cerebrospinal fluid diversion such as a temporary external ventricular drain or ventriculoperitoneal shunt may still be required,⁷⁸ and if the clinical condition allows, neoadjuvant treatment with an mTORi may facilitate surgery by tumor shrinkage, improving tumor-brain interphase and reducing tumor vascularity.⁷⁹ Treatment of large, symptomatic SEGA with an mTORi in lieu of urgent surgery⁸⁰ or to relieve obstructive hydrocephalus due to SEGA⁸¹ has been reported. However, the mTORi treatment is primarily recommended for individuals with asymptomatic growing or large SEGAs, those with mild to moderate symptoms (including asymptomatic ventriculomegaly), and those who are not surgical candidates or prefer medical treatment over surgery.⁸² mTORi may also be favored for potential benefit to treat additional manifestations of TSC that frequently coexist in patients with SEGA, such as medically refractory epilepsy⁸³ or renal angiomyolipoma.⁸⁴ Well-designed studies demonstrate long-term effects of their use.^{85,86} Shared decision-making with the patients

and their parents in selecting the best treatment option should take into consideration the surgical risks (including availability of an experienced surgical team), mTORi availability, cost, expected duration of therapy, and potential side effects, other TSC manifestations (renal angiomyolipoma, refractory seizures, etc.), and SEGA-related factors (location, multiple SEGAs, etc.)^{87,88} (Category 1).

Treatment with mTORi appears to be dose-responsive,⁸⁹ and after achieving a primary tumor response it may be possible to reduce dosing to minimize adverse events while maintaining tumor stability.⁹⁰ mTORis appear to be safe in young children aged less than three years^{91–93} (Category 1).

Optimal outcome is associated with early detection and treatment,⁹⁴ so surveillance by MRI scanning should be performed every one to three years in all individuals with TSC until age 25 years when SEGA is most prevalent.⁹⁵ It should be noted, however, that recent studies reveal that known SEGAs may enlarge during adulthood⁹⁵ and in rare instances newly present in adulthood.⁹⁶ Thus, lifelong awareness regarding potentially growing SEGA is warranted. Within the recommended one- to three-year interval, scans should be performed more frequently in those asymptomatic patients with SEGA whose SEGAs are larger or growing or who are developmentally or cognitively disabled and cannot reliably report subtle neurological symptoms (Category 2A).

Epilepsy

The majority of infants with TSC will experience their first seizure before age one year,⁹⁷ and seizure control should be considered a medical emergency in infants with TSC because refractory epilepsy is strongly correlated with poor developmental and cognitive outcomes^{31,32,97,98} and earlier recognition and treatment of epilepsy in infancy is associated with better long-term neurological outcomes.^{31,33} Routine EEG in asymptomatic infants with TSC should be obtained every six weeks up to age 12 months and every three months up to age 24 months, as abnormal EEG very commonly precedes onset of clinical seizures,^{29,30} allowing for the earliest possible intervention (Category 1). It should be noted that the first seizure types to occur in TSC can be infantile spasms, focal seizures, or both, and infantile spasms in TSC are frequently not accompanied by hypsarrhythmia.³⁰

There is strong evidence for the efficacy of vigabatrin for the treatment of infantile spasms associated with TSC^{31,33,99,100}; therefore, we recommend vigabatrin as the first-line treatment. The prescriber should be aware of the possible side effects, particularly potential retinal toxicity associated with peripheral vision loss, and how to monitor for these. While the risk of retinal toxicity or abnormalities on brain MRI may correlate with total cumulative dose,^{101,102} improved control of infantile spasms also correlates with dose.^{103,104} Therefore, the relative risks of uncontrolled epilepsy and treatment-related adverse effects should be discussed and weighed by health care providers and parents/caregivers together. Vigabatrin should be titrated rapidly up to 100 to 150 mg/kg/day. If resolution of the hypsarrhythmia pattern on EEG (when present) and abatement of infantile spasms does not occur within two weeks, adrenocorticotropic hormone (ACTH), synthetic adrenocorticotropic hormone, or prednisolone can be added as second-line therapy¹⁰⁵ (Category 1).

The recently completed EPISTOP study found that preventative vigabatrin treatment resulted in reduced risk of seizures, infantile spasms, and drug-resistant epilepsy; however, there was no difference in the prevalence of developmental delay or autism at age two years.^{34,35} These results are promising, but the consensus committee determined that additional evidence is needed before preventative treatment with vigabatrin can be recommended for all infants with TSC universally. The PREVeNT clinical trial

TABLE 4.
Surveillance and Management Recommendations for Patients Already Diagnosed With Definite or Possible TSC

Organ System or Specialty Area	Recommendations
Genetics	Offer genetic testing and family counseling if not done previously.
Brain	<p>Obtain MRI of the brain every 1–3 yr in asymptomatic patients with TSC younger than age 25 yr to monitor for new occurrence of SEGA. Patients with large or growing SEGA, or with SEGA causing ventricular enlargement who are asymptomatic, should undergo MRI scans more frequently, and the patients and their families should be educated regarding the potential of new symptoms. Patients with asymptomatic SEGA in childhood should continue to be imaged periodically as adults to ensure there is no growth.</p> <p>Surgical resection should be performed for acutely symptomatic SEGA. Cerebrospinal fluid diversion (shunt) may also be necessary. Either surgical resection or medical treatment with mTORi may be used for growing but otherwise asymptomatic SEGA. For large tumors, if clinical condition enables, neoadjuvant treatment with mTORi may facilitate surgery. Minimally invasive surgical techniques may increase surgical safety in selected patients. In determining the best treatment option, discussion of the complication risks, adverse effects, cost, length of treatment, and potential impact on TSC-associated comorbidities should be included in the decision-making process.</p> <p>Obtain routine EEG in asymptomatic infants with TSC every 6 weeks up to age 12 months and every 3 months up to age 24 months, as abnormal EEG frequently precedes onset of clinical seizures.</p> <p>Obtain routine EEG in individuals with known or suspected seizure activity. The frequency of routine EEG should be determined by clinical need rather than a specific defined interval. Prolonged video-EEG, 24 hr or longer, is appropriate when seizure occurrence is unclear or when unexplained sleep, behavioral changes, or other alteration in cognitive or neurological function is present.</p> <p>Vigabatrin is the recommended first-line therapy for infantile spasms. ACTH, synthetic ACTH, or prednisolone can be used if treatment with full-dose vigabatrin for 2 weeks has not correlated with clinical and EEG improvement.</p> <p>Other than infantile spasms, antiseizure medications for other seizure types in TSC should generally follow that of other epilepsies. Everolimus and a specific cannabidiol formulation are approved by regulatory authorities for treatment of seizures associated with TSC. No comparative effectiveness data exist to recommend antiseizure medications, everolimus, cannabidiol, or dietary therapies over one another in specific subsets of patients.</p> <p>Epilepsy surgery should be considered for TSC patients with refractory seizures, seizures, particularly after failing three medications. Special consideration should be given to children at younger ages experiencing neurological regression, and evaluation for surgery should be performed at centers with experience and expertise in TSC.</p>
TAND	<p>Perform annual screening for TAND, using validated screening tools such as the TAND Checklist (https://tandconsortium.org/checklists/). Screening may be done more frequently depending on clinical needs. When any concerns are identified on screening, proceed to further evaluations by appropriate professionals to diagnose and treat the relevant TAND manifestations. Perform comprehensive formal evaluation for TAND across all levels of TAND (see Fig of TAND umbrella) at key developmental time points: infancy (0–3 yr), preschool (3–6 yr), premiddle school (6–9 yr), adolescence (12–16 yr), early adulthood (18–25 yr), and as needed thereafter.</p> <p>Refer to appropriate professionals for the management/intervention of relevant TAND manifestations. Interventions should be personalized to the TAND profile of each individual and be based on evidence-based practice guidelines/practice parameters for individual manifestations (e.g., autism spectrum disorder, attention-deficit/hyperactivity disorder, anxiety disorder). Aim for early identification of TAND manifestations and early intervention.</p> <p>Many people with TSC have academic/scholastic difficulties. Therefore, always consider the need for an individual educational program.</p> <p>Sudden and unexpected change in behavior should prompt physical evaluation to look at potential medical causes (e.g., SEGA, seizures, renal disease, medications).</p> <p>Provide psychological and social support to families and caregivers and ensure strategies are in place to support caregiver well-being. Continue to provide parent/caregiver education and training about TAND to ensure families know what to look out for in emerging TAND manifestations across the lifespan.</p>
Kidney	<p>Obtain MRI of the abdomen to assess for the progression of angiomyolipoma and renal cystic disease every 1–3 years throughout the lifetime of the patient.</p> <p>Assess renal function including determination of glomerular filtration rate, proteinuria, and blood pressure at least annually. Embolization followed by corticosteroids is the first-line therapy for angiomyolipoma presenting with acute hemorrhage. Nephrectomy is to be avoided. For asymptomatic, growing angiomyolipoma measuring larger than 3 cm in diameter, treatment with an mTORi is the recommended first-line therapy. Selective embolization or kidney-sparing resection are acceptable second-line treatments for asymptomatic angiomyolipoma.</p>
Lung	<p>Inquire about smoking, occupational exposures, connective tissue disease symptoms, chyle leak, and pulmonary manifestations, such as dyspnea, cough, and spontaneous pneumothorax in all adult patients at each clinic visit.</p> <p>For adult females with a negative screening chest CT who remain asymptomatic, repeat to screen for the presence of LAM every 5–7 years through menopause.</p> <p>For patients with evidence of cystic lung disease consistent with LAM on screening chest CT, follow-up scan intervals should be determined on a case-by-case basis depending upon the individual circumstances, such as the presence or absence of symptoms, the ability to perform reliable PFTs, pre-existing use of mTORis for other TSC indications, treatment response (or the lack thereof), or development of other pulmonary complications.</p> <p>Perform routine serial pulmonary function test monitoring at least annually in patients with evidence of LAM on chest CT, and more frequently in patients who are progressing rapidly or who are being monitored for response to therapy.</p> <p>Use mTORi for treatment of LAM in patients with abnormal lung function (FEV1 < 70% predicted), physiological evidence of substantial disease burden (abnormal DLCO [$<80\%$ or less than lower limit of normal (when available)]), air trapping (RV > 120%), resting or exercise-induced oxygen desaturation, rapid decline (rate of decline in FEV1 > 90 mL/year), and problematic chylous effusions.</p> <p>Counsel patients regarding the risk of pregnancy and exogenous estrogen use. Avoid routine use of hormonal therapy or doxycycline for the treatment of LAM. Advise patients against tobacco smoke exposure including the use of electronic cigarettes and vaping.</p> <p>Trial inhaled bronchodilators in patients with symptoms of wheezing, dyspnea, chest tightness, or obstructive defect on spirometry, with continued use in patients who derive symptomatic benefit</p> <p>Consider measurement of annual VEGF-D levels in patients who are unable to perform reliable pulmonary function tests to monitor adequacy of pharmacodynamic suppression of the mTOR pathway.</p>

(continued on next page)

TABLE 4. (continued)

Organ System or Specialty Area	Recommendations
Skin	<p>Encourage age-appropriate vaccinations, such as annual influenza vaccination, inactivated recombinant shingles vaccination, and both 13-valent and 23-valent pneumococcal vaccinations. Patients on mTOR inhibitors should receive the recombinant varicella vaccine regardless of age and avoid all live vaccines.</p> <p>Educate patients and families about the signs and symptoms of a pneumothorax and advise them to seek medical attention if they experience any of these symptoms. Offer pleurodesis following the first episode of pneumothorax rather than waiting for a recurrent event. Counsel patients that pleurodesis does not preclude future lung transplantation.</p> <p>Perform annual skin examinations for children with TSC. Adult dermatologic evaluation frequency depends on the cutaneous manifestation. Close surveillance and intervention are generally recommended for TSC-related skin lesions that rapidly change in size and/or number; cause functional interference, pain, or bleeding; or inhibit social interactions.</p> <p>Provide ongoing education on sun protection.</p> <p>For flat or minimally elevated lesions, topical mTORi treatment is recommended. Watch for improvement in skin lesions over several months; if lesions do not improve, or if earlier intervention is indicated, then consider use of surgical approaches. For protuberant lesions, consider surgical approaches (e.g. excision, lasers).</p>
Teeth	<p>Perform a detailed clinical dental inspection/examination at minimum every 6 months. Take a panoramic radiograph to evaluate dental development or if asymmetry, asymptomatic swelling, or delayed/abnormal tooth eruption occurs. Enamel pits may be managed by preventive measures as first-line treatment (sealants, fluoride). These pits may be managed by restorations if preventive measures fail, or if symptomatic, carious, or there is an aesthetic concern. Symptomatic or deforming oral fibromas and bony jaw lesions should be treated with surgical excision or curettage when present.</p>
Heart	<p>Obtain an echocardiography every 1-3 years in asymptomatic pediatric patients until regression of cardiac rhabdomyomas is documented. More frequent or advanced diagnostic assessment may be required for symptomatic patients.</p> <p>Obtain electrocardiography every 3 to 5 years in asymptomatic patients of all ages to monitor for conduction defects. More frequent or advanced diagnostic assessment such as ambulatory and event monitoring may be required for symptomatic patients.</p>
Eye	<p>Perform annual ophthalmic evaluation for those with or without visual symptoms at baseline. Rare cases of aggressive lesions or those causing vision loss due to their location affecting the fovea or optic nerve may require intervention. mTOR inhibitors have been used with some success to treat problematic retinal astrocytic hamartomas.</p> <p>For patients receiving vigabatrin, there are specific concerns related to visual field loss, which appears to correlate with total cumulative dose. Physicians responsible for monitoring children on vigabatrin can offer serial fundoscopic examinations to detect retinal changes.</p>
Other	<p>Identification of unexpected functional and nonfunctional PNETs have been found during abdominal MRI surveillance in individuals with TSC. Further monitoring and evaluation should be referred to endocrinology.</p>

Abbreviations:

- ACTH = Adrenocorticotrophic hormone
- CT = Computed tomography
- DLCO = Diffusing capacity of the lungs for carbon monoxide
- EEG = Electroencephalography
- FEV1 = Forced expiratory volume in one-second
- LAM = Lymphangioleiomyomatosis
- MRI = Magnetic resonance imaging
- mTOR = Mechanistic target of rapamycin
- mTORi = mTOR inhibitor
- PFT = Pulmonary function test
- PNET = Pancreatic neuroendocrine tumor
- RV = Residual volume
- SEGA = Subependymal giant cell astrocytoma
- TSC = Tuberous sclerosis complex
- TAND = TSC-associated neuropsychiatric disorder
- VEGF-D = Vascular endothelial growth factor-D

(NCT02849457), with results expected in the next year, should address this need.

Routine EEG is recommended in individuals with known or suspected seizure activity, but frequency should be determined by clinical need rather than a specifically defined interval. Prolonged (24 hours or longer) video-EEG is appropriate when seizure occurrence is unclear or when unexplained sleep, behavioral changes, or other alteration in cognitive or neurological function is present (Category 2A).

Seizures in adults with TSC can begin at any age, can worsen, or can abate over the individual's lifespan. Also, seizure semiology can change in adults with TSC (i.e., focal seizures with impaired awareness may become bilateral, tonic-clonic seizures). Any adult with TSC presenting with new-onset seizures or changed seizure semiology should be examined for non-TSC-related events, which can occur with or without TSC (e.g., glioma, subarachnoid hemorrhage, stroke, etc.).

Other than for infantile spasms, antiseizure medication or dietary therapy selection in TSC should generally follow that of other epilepsies. The mTOR inhibitor everolimus⁸³ and a specific

formulation of cannabidiol¹⁰⁶ have been specifically evaluated in randomized controlled trials to treat seizures in TSC and found to be effective and well-tolerated (Category 1). Both are now approved by many regulatory authorities for adjunctive treatment of seizures associated with TSC. However, no comparative effectiveness data exist to recommend specific antiseizure medications, everolimus, or cannabidiol over one another in a particular patient. Clinicians should be aware that both everolimus¹⁰⁷ and cannabidiol¹⁰⁸ have important drug interactions with other antiseizure medications, including with each other.^{109,110} Dietary interventions, including a ketogenic diet^{111,112} or low-glycemic index treatment,¹¹³ may be an effective nonpharmacological therapy for patients with TSC with intractable epilepsy, including infantile spasms refractory to vigabatrin and hormonal therapies.

Epilepsy surgery should be considered for patients with refractory TSC, particularly after failing three medications.¹¹⁴⁻¹¹⁶ Special consideration should be given to children at younger ages experiencing neurological regression,^{117,118} and evaluation for surgery should be performed at specialized epilepsy centers with experience and expertise in TSC (Category 2A).

Vagus nerve stimulation can be used in TSC for medically refractory epilepsy if surgery is unsuccessful or not an option.¹¹⁹ There are early data suggesting that responsive neurostimulation may be effective in select adults with TSC and intractable seizures.¹²⁰

TSC-associated neuropsychiatric disorder (TAND)

Annual screening for TAND should be performed throughout the lifespan using validated screening tools such as the TAND Checklist (<https://tandconsortium.org/checklists/>)^{37,38} or more frequently if clinically indicated. If concerns are identified on screening, the individual should be referred for evaluation by appropriate professionals to diagnose and treat the relevant TAND manifestations³⁹ (Category 1). In addition to annual screening, formal evaluation of TAND is recommended at key developmental time points (Table 4)^{37,39} (Category 2A). This evaluation may require input from a range of professionals including psychiatrists, psychologists, neuropsychologists, or other health care, educational, and neurodevelopmental experts. Sudden and unexpected change in behavior should prompt physical evaluation to look at potential medical causes (e.g., SEGA, seizures, renal disease, medications)¹²¹ (Category 1).

Early identification and intervention for TAND manifestations is important for optimal outcomes.¹²¹ No TSC-specific interventions currently exist for any TAND manifestations. However, evidence-based treatment strategies exist for individual disorders under the TAND umbrella, e.g., autism spectrum disorder, attention-deficit/hyperactivity disorder, and anxiety disorders. Interventions by appropriate specialists should be personalized to the TAND profile of each individual and based on evidence-based practice guidelines or parameters for individual manifestations.

Many people with TSC have academic or scholastic difficulties and may benefit from an individualized educational plan^{11,122,123} (Category 2A). Scholastic difficulties may have an impact on occupational functioning into and throughout adult life.

Families and caregivers may also need psychological and social support because of the potential impact of TSC on the entire family, so strategies should be in place to provide or refer to appropriate support^{40,41} (Category 2B). Individuals, families, and caregivers should be educated about TAND so that they can identify emerging TAND manifestations across the lifespan^{40,41} (Category 2B).

Kidney

For asymptomatic, growing angiomyolipoma measuring larger than 3 cm in diameter, treatment with an mTORi is recommended as the first-line therapy.^{84,124–126} The EXIST-2 study demonstrated that in 30% of patients on low-dose everolimus (≤ 5 mg daily), control of angiomyolipoma was maintained,¹²⁵ and additional evidence¹²⁷ suggests that this benefit generalizes to most patients with TSC—not only those who participated in EXIST-2. Protocols for safe use of everolimus, including preimmunization, should be followed.¹²⁸ The demonstrated continued tolerability is preferable to the renal damage caused by angiomyolipoma progression or by surgical embolization or ablative therapies, as pre-emptive intervention with most recent studies have shown impressively favorable outcomes with preserved GFR and low rates of bleeding, hypertension, or other complications⁴⁸ (Category 1).

At minimum, annual clinical assessment of kidney function, proteinuria, and blood pressure is required in those with normal values, and more frequently in those with findings of renal impairment or hypertension. Transient or variable proteinuria may be a side effect of mTORis but not usually an indication to discontinue treatment.¹²⁴ Control of hypertension is also critical, so

accurate measurements of blood pressure for patients are crucial, including using age-specific criteria for children.¹²⁹ Patients with hypertension should be treated with an inhibitor of the renin-aldosterone-angiotensin system as first-line therapy; current experience does not support previous advice that angiotensin-converting enzyme inhibitors should be avoided in those treated with an mTORi¹³⁰ (Category 1). Furthermore, angiotensin-converting enzyme inhibitors and angiotensin receptor blockers clearly prolong kidney function in other chronic kidney disease conditions and have been associated with a reduced rate of angiomyolipoma formation when used in the young.¹³¹

The minority of patients who develop advanced renal failure can still benefit from mTORi therapy to prevent bleeding and to possibly slow or stop decline in renal function.¹²⁴ For individuals with TSC, all options for renal replacement therapy should be considered, including those with neurological impairment¹³² (Category 2B).

Surveillance imaging for polycystic disease, renal cell carcinoma, or other tumors^{133,134} and for changes in angiomyolipoma should also be performed. Abdominal MRI, which can be strategically conducted at the same time as brain surveillance imaging, is the preferred imaging modality. However, if MRI is not available, CT can still provide useful information.¹³⁵ The frequency of imaging should be one to three years, with yearly scans preferred for tumors that are approaching 3 cm in size and/or appear to be growing. Longer intervals are acceptable in some specific situations in which no tumors are seen or only small tumors (<1 cm) are seen with minimal growth over time. Selective embolization followed by corticosteroids,¹³⁶ kidney-sparing resection, or ablative therapy for exophytic lesions are acceptable second-line therapy for asymptomatic angiomyolipoma if medical treatment with an mTORi is contraindicated.¹²⁶ For acute hemorrhage, embolization followed by corticosteroids is more appropriate.¹³⁷ Nephrectomy is to be avoided because of the high incidence of complications and increased risk of future renal insufficiency, end-stage renal failure, and the poor prognosis that results from chronic kidney disease^{41,126} (Category 2A).

Fat-poor angiomyolipoma are common in patients with TSC, occurring more commonly in children and those with new angiomyolipoma.⁴⁸ Fat-poor angiomyolipoma can be distinguished from carcinoma, because fat-poor angiomyolipoma typically have a slower growth velocity (<5 mm/year [in diameter]) than carcinoma. Also, fat-poor angiomyolipoma characteristically grow out of the kidney between other structures rather than compressing surrounding structures, which is more commonly a characteristic of carcinoma.⁴² When a lesion cannot be confidently identified as a fat-poor angiomyolipoma, a needle biopsy using a sheath technique or an open biopsy may be considered (Category 2A). Review of biopsy results by a TSC expert pathologist is strongly recommended, with staining using specific antibodies including HMB-45 to distinguish a fat-poor angiomyolipoma from a renal cell carcinoma.¹³⁸

Lung

Adult women with TSC should be periodically screened for the presence of LAM with chest CT. Following a negative screening CT for LAM, repeat CT imaging should be obtained if pulmonary symptoms develop or approximately every five to seven years for asymptomatic females through menopause. In patients with evidence of cystic lung disease consistent with LAM on the screening CT, subsequent follow-up CT scan intervals should be determined based on individual circumstances such as the presence or absence of symptoms, the ability to perform reliable PFTs, pre-existing use of mTORis for other TSC indications, treatment response (or the lack

thereof), or development of other pulmonary complications. When chest CT is performed, the “as low as reasonably achievable” principle should be employed to minimize the radiation dose to the patient¹³⁹ (Category 2A).

In individuals with evidence of LAM on CT, baseline PFTs and six-minute walk test should be obtained, and full PFTs should be repeated annually to monitor the rate of disease progression. More frequent spirometry (every three to six months) should be considered in (1) patients with a new LAM diagnosis to establish a trajectory of disease progression, (2) patients with progressive symptoms, (3) patients with advanced disease and limited pulmonary reserves, and (4) to monitor treatment response in patients taking mTORis. Postbronchodilator spirometry is preferred for all patients, to limit variability due to reversible airflow obstruction. In patients who are unable to perform PFTs because of cognitive impairment or other reasons, serial CT imaging may be the best method to assess progression (Category 2A).

The mTORi sirolimus is recommended as the first-line treatment for qualifying patients with LAM¹⁴⁰ (Category 1). In patients unable to perform reliable PFTs, the decision to start sirolimus may be based upon an overall assessment of disease severity and rate of progression as determined by changes in one or more of the following: extent of cystic lung disease on chest CT, need for supplemental oxygen at rest or with exercise, dyspnea on exertion with minimal activities, recurrent pneumothorax, and elevated serum VEGF-D levels. Consideration may also be given to annual measurement of serum VEGF-D levels as a pharmacodynamic marker of treatment effect, although this use of the test has not been validated (Category 2B).

A substantial proportion of patients with TSC who are discovered to have LAM may already be taking everolimus for other indications.⁸²⁻⁸⁴ In these circumstances, given the extensive molecular similarity and evidence of efficacy in an open-label phase 2 study,¹⁴¹ we recommend continued treatment with everolimus and serial PFT monitoring rather than switching to sirolimus (Category 2A).

Patients should be counseled that pregnancy in LAM has been associated with accelerated lung function decline and increased risk of pneumothorax.¹⁴²⁻¹⁴⁵ Lung transplantation remains a viable management option for patients with TSC with end-stage LAM.^{146,147} Prior pleurodesis is not a contraindication for lung transplantation.¹⁴⁶ However, the presence of other TSC-related comorbidities, including cognitive impairment, renal dysfunction, or angiomyolipoma burden, may influence candidacy as well as outcomes following lung transplantation (Category 2B).

Skin

Annual skin examinations are recommended for children with TSC. The frequency of dermatologic evaluation in adults depends on the severity of cutaneous manifestations. Close surveillance and intervention are recommended for TSC-related skin lesions that rapidly change in size and/or number, cause functional interference, cause pain or bleeding, or inhibit social interactions. Longitudinal follow-up with digital photography may be used to monitor skin changes.

Many individuals show improvement in TSC-related skin lesions while taking a systemic mTORi for other manifestations related to TSC¹⁴⁸⁻¹⁵⁰ (Category 1). In individuals with an inadequate skin response, surgical approaches may be used, taking into consideration the potential for impaired wound healing while on an mTORi. The risk-benefit ratio of a systemic mTORi generally excludes their use for TSC skin lesions alone. Evidence is currently lacking to demonstrate an additive benefit of topical sirolimus (rapamycin) in patients on systemic therapy.

Topical sirolimus is safe and effective for treating facial angiofibromas^{151,152} (Category 1), and it may also improve other TSC skin lesions¹⁵³⁻¹⁵⁵ (Category 2A). Topical medication is generally applied once or twice daily and compounded by specialty pharmacies at 0.1% to 1% concentration in a variety of vehicles. In Japan, sirolimus gel 0.2% (Rapalimus, Nobelpharma) was approved by regulatory authorities in 2018. Skin lesions that are smaller and flatter appear to respond better to topical sirolimus than bulky lesions, so early treatment is recommended. Long-term therapy will likely be required to maintain benefit.^{153,154} Adverse effects of topical sirolimus are generally mild, such as application-site skin irritation, dry skin, or acne.¹⁵⁴ Systemic absorption of topical sirolimus is typically below the level of detection.^{151,152} Sirolimus has anticancer effects, but one study of topical sirolimus reported increased skin tumors in mice treated with a regimen of topical sirolimus and solar simulated light.¹⁵⁶ Pending clinical studies, good sun protection is recommended while using topical sirolimus.

Surgical approaches can be effective for treating TSC skin lesions^{64,157,158} (Category 2B). Indications for surgical treatment include bleeding, irritation, pain, disfigurement, or impaired function (including vision, breathing, or mobility). Immediate surgical intervention may be necessary in some patients. For others, the timing of elective surgery should be determined by rate of growth, risk of recurrence, and likelihood of scarring. Younger children with flat angiofibromas may benefit from pulsed-dye laser to reduce facial erythema, whereas use of ablative lasers for larger angiofibromas is preferable in later adolescence when the rate of recurrence is lower. Pulsed-dye laser has minimal risk of dyspigmentation and scarring, but multiple treatments are usually required, and benefits are usually short-lived when used alone. Ablative approaches flatten the lesions, but general anesthesia is often required, and postoperative recovery can take up to a few weeks.¹⁵⁸ Long-term complications include dyspigmentation, scarring, change of skin texture, and regrowth.

Teeth

A detailed clinical dental inspection or examination should be performed at minimum every six months. Patients with special needs and difficulty maintaining oral hygiene may benefit from routine evaluation every three months.¹⁵⁹ A panoramic radiograph may be indicated to evaluate dental development or if asymmetry, asymptomatic swelling, or delayed or abnormal tooth eruption occurs. Enamel pits may be managed by preventive measures as first-line treatment (sealants, fluoride). Enamel pits may be managed by restorations if preventive measures fail, or if symptomatic, carious, or there is an esthetic concern. Symptomatic or deforming oral fibromas and bony jaw lesions should be treated with surgical excision or curettage. Referral to a dentist with advanced training should occur for symptomatic or asymptomatic facial swelling to rule out odontogenic origin or intraoral pain associated with teeth or intraoral lesions.

Heart

Until regression of cardiac rhabdomyomas is documented, follow-up echocardiography should be performed every one to three years in asymptomatic patients. In addition, 12-lead ECG is recommended at minimum every three to five years to monitor for conduction defects. In patients with clinical symptoms, additional risk factors, or significant abnormalities on routine echocardiography or ECG, more frequent interval assessment may be needed and may include ambulatory event monitoring (Category 1). Patients with TSC with known history of arrhythmia or ECG abnormalities that indicate an increased risk for arrhythmia should be

informed that some prescription and nonprescription medications and natural supplements may further increase the risk of arrhythmia. Such individuals should verify the safety and suitability with their cardiologist or TSC specialist before beginning a new medication or supplement.

Eye

For individuals without ophthalmic manifestations of TSC or for those without visual symptoms at baseline, re-evaluation is recommended annually, or as new clinical concerns arise. The majority of retinal astrocytic hamartomas do not cause vision loss; however, rare cases of aggressive lesions or those causing vision loss due to their location affecting the fovea or optic nerve have been reported.¹⁶⁰⁻¹⁶³ In such cases intervention with laser, photodynamic therapy, intravitreal anti-VEGF, intravitreal steroids, or surgery may be appropriate.^{162,163} More recently, mTORis have been used with some success to treat problematic astrocytic hamartomas.^{160,161}

For patients receiving vigabatrin, there are specific concerns related to visual field loss, which appear to correlate with total cumulative dose.^{164,165} Serial ophthalmologic examination every three months is recommended by the US Food and Drug Administration. Other modes of surveillance include testing of visual evoked potentials, electroretinography, and optical coherence tomography of the retinal nerve fiber layer. Although these tests can be helpful, they have limitations and are somewhat impractical as they can require sedation. The American Association for Pediatric Ophthalmology and Strabismus supports serial dilated fundus examination for children using vigabatrin¹⁶⁶ (Category 2B).

Other

Due to surveillance protocols, there is a growing number of reports of functional and nonfunctional pancreatic neuroendocrine tumors (PNETs) in association with TSC. Functional PNETs are often identified early based on the presence of symptoms. Preliminary reports note instances in which nonfunctional PNETs were missed during early surveillance.¹⁶⁷ To address the potential gap in care, the endocrine group recommends special attention to pancreatic lesions on abdominal imaging studies performed for the surveillance of renal lesions and consideration of abdominal MRI with fine pancreatic cuts.¹⁶⁸ Compared with other tumor susceptibility syndromes, the risk for endocrine tumors in TSC remains low.^{169,170} Biopsy of nonfunctional lesions is recommended only when lesions are unusually large, growing, symptomatic, multiple, or exhibit other suspicious characteristics. Functional PNETs require standard-of-care evaluation and management as in patients without TSC.

In the event unexpected thyroid nodules appear on chest CT scans of patients with TSC, those nodules should be evaluated as per standard of care.¹⁷¹ There is no evidence of increased risk of thyroid nodules or thyroid cancer in patients with TSC.¹⁷²

Other clinical considerations in patients with TSC

The previously published recommendations for surveillance and management of TSC highlighted several key areas regarding care coordination for individuals with TSC. Those guidelines have been translated into 17 languages and primarily focused on the role of specialized TSC clinics and advocacy groups in educating patients, families, and health care professionals on the manifestations, natural history, and care for people with TSC. An important addition to this section concerns the use of mTORis in TSC care, which are approved by many regulatory authorities worldwide and commonly used for certain manifestations of TSC.

Practical guidance for the use of mTOR inhibitors in patients with TSC

The use of mTORis, sirolimus and everolimus, has become the cornerstone in the management of tumors associated with TSC. The first TSC-specific regulatory approval occurred in 2010, when everolimus was approved by the US Food and Drug Administration for the treatment of SEGA. Today, everolimus is now approved in many countries around the world for the treatment of renal angiomyolipoma and/or and partial-onset epilepsy associated with TSC in addition to SEGA. Sirolimus was first approved for the treatment of LAM associated with TSC in Japan in 2014, followed by approval in the United States a year later.

When initiating therapy with an mTORi, baseline laboratory studies should include a fasting lipid panel, comprehensive metabolic panel, cystatin C quantification, urine analysis, and complete blood count with differential. These panels should be repeated shortly after treatment is started in addition to measurements of mTORi trough level and levels of concomitant medications, particularly if they are strong enzyme inhibitors or inducers (e.g., some antiepileptic medications such as carbamazepine and oxcarbazepine are known to reduce mTORi trough levels, whereas some antimicrobials such as clarithromycin and ketoconazole are known to increase mTORi trough levels).¹⁷³ Cannabidiol is reported to increase mTORi trough levels.^{109,110} Laboratory studies including mTORi trough levels should be rechecked periodically during treatment, particularly when a strong enzyme inhibitor or inducer is introduced to a patient's treatment regimen. In general, adverse events of systemic therapy with mTORis are mild to moderate,⁸⁷ including patients treated at young ages.^{91,93} However, when such therapies are prescribed, it is not uncommon for adverse events, such as oral ulceration, hyperlipidemia, and hyperglycemia, to necessitate dose reduction or temporary suspension of treatment.^{174,175} Individuals undergoing major surgical procedures while on mTORi therapy should be informed about potential impairment of wound healing and potential immunosuppressive properties that can exacerbate infections in rare instances or impact the safety of immunization with live vaccines (which commonly include vaccines used against measles, mumps, rubella, varicella, and yellow fever).^{174,175} mTORi therapy also has been associated with menstrual cycle disturbances¹⁷⁶ and ovarian cysts.¹⁷⁷ Standard practice is to temporarily halt mTORi therapy one to two weeks before planned surgeries or live-vaccine immunizations or during any prolonged or new-onset significant infections or other adverse effects and then resume treatment after recovery (typically one to two weeks after vaccination and two to four weeks after surgery). Recurrent or severe adverse events may also require lower dosing of the mTORi when treatment is resumed. Note that benefit has been demonstrated even if resultant blood trough levels of mTORi are at the lower end or even below the recommended reference range (5 to 15 ng/mL).^{107,178}

Quality of life and burden of care

TSC may present a severe physical, mental, and financial burden to both the individuals with TSC and their caregivers. As described previously,⁴¹ many individuals with TSC experience TAND. Management of stress associated with TSC and its complexities is crucial to the mental well-being of the individual with TSC and caregivers. Health care providers should help families and caregivers make connections with secondary care teams, including therapists, social workers, and other counselors to learn about their region's resources such as respite care and other mental health support programs. Caregivers' and siblings' physical and mental health should not be overlooked.

Access to care

The International Tuberous Sclerosis Complex Consensus Group is composed of more than 80 TSC specialists from 14 countries (six continents) with a broad range of medical expertise and specialization. These updated consensus recommendations are based on extensive practical experience and best available scientific evidence and as such represent the most up-to-date standard of care for individuals with TSC throughout their lifespan, regardless of where they live. Effort should be made to implement and adhere to these standards fully whenever possible. However, we recognize that significant barriers at the individual, regional, or country level frequently exist that can hinder availability or access to specific technologies, treatments, or medical specialists on which some consensus recommendations depend. The previous guidelines⁸ have been translated into 17 languages, and in Portugal these were accepted as care standards for TSC and formally adopted by the National Ministry of Health. Several additional international groups have published their approach to implementing the previous guidelines from 2012^{179–181}; these articles may serve as manuals for regions of similar size, economies, and/or health systems. Local medical providers and specialists may also need to adapt specific recommendations in such circumstances as best as they are able while continuing efforts to remedy and overcome these barriers for the optimal treatment of their patients.

Local and international advocacy groups are essential partners in helping individuals and families navigate the TSC care landscape in their region, providing psychosocial support and educating health care providers and individuals and families affected by TSC. In the United States, the TSC Alliance serves this role (www.tscalliance.org), as do the 38 TSC advocacy groups from different countries of TSCi (www.tscinternational.org). TSCi has written a companion piece white paper published contemporaneously, *Beyond the Guidelines: How we can improve health care for people with tuberous sclerosis complex (TSC) around the world*, which focuses the issues of care coordination and access to care through a global lens.

Care coordination and transition of care

Health care transition from pediatric to adult care is challenging in the chronic disease setting, even more so in TSC due to its involvement of many major organ systems requiring focused attention from specialists. Ideally, a multidisciplinary team would manage clinical transition.^{41,182,183} Two recent papers discuss the transition from pediatric to adult care in greater detail, specifically in the care of individuals with TSC.^{184,185} The Child Neurology Foundation recently convened a multidisciplinary team that produced a consensus statement outlining eight common principles that define the child neurologist's role in this important transition.¹⁸⁶

Given the complexities and variety of manifestations across the lifespan, it is essential to have support from a local health care professional available (e.g., primary care physician), in addition to coordinated support from TSC specialists and other care providers that often are located at regional or national referral centers.¹⁸⁷ In countries where government policies to assist patients with rare diseases have not yet been implemented, advocacy group-supported research initiatives centered at teaching hospitals have been instrumental in establishing multispecialty medical teams for the care of individuals with TSC. Secure software for telecommunications may provide additional opportunities for coordinated care among patients, local medical providers, and TSC specialists when medically appropriate and permitted by government regulators.

Acknowledgments

The meeting of International TSC Consensus Group coauthors and working group coauthors at the 2018 World TSC Conference was sponsored and organized by the TSC Alliance. Sponsors of the 2018 World TSC Conference played no role in the planning and did not attend the meeting of the Consensus Group, and they had no influence on the resulting recommendations. Sponsors of the 2018 World TSC Conference were Novartis Pharmaceuticals, the Rothberg Institute for Childhood Diseases, Upsher-Smith Laboratories, LivaNova, Depomed, Greenwich Biosciences, Mallinckrodt Pharmaceuticals, UCB, Lundbeck, Amneal Pharmaceuticals, Aquestive Pharmaceuticals, MassMutual, Ovid Therapeutics, West Therapeutics Development and Eolas Pharma, WNC & Associates, and many individual and non-for-profit donors to the TSC Alliance.

References

1. Crino PB, Nathanson KL, Henske EP. The tuberous sclerosis complex. *N Engl J Med*. 2006;355:1345–1356.
2. Jozwiak S, Schwartz RA, Janniger CK, Bielicka-Cymerman J. Usefulness of diagnostic criteria of tuberous sclerosis complex in pediatric patients. *J Child Neurol*. 2000;15:652–659.
3. Osborne JP, Fryer A, Webb D. Epidemiology of tuberous sclerosis. *Ann N Y Acad Sci*. 1991;615:125–127.
4. Northrup H, Krueger DA. Tuberous sclerosis complex diagnostic criteria update: recommendations of the 2012 international tuberous sclerosis complex consensus conference. *Pediatr Neurol*. 2013;49:243–254.
5. Ebrahimi-Fakhari D, Mann LL, Poryo M, et al. Incidence of tuberous sclerosis and age at first diagnosis: new data and emerging trends from a national, prospective surveillance study. *Orphanet J Rare Dis*. 2018;13:117.
6. Roach ES, Gomez MR, Northrup H. Tuberous sclerosis complex consensus conference: revised clinical diagnostic criteria. *J Child Neurol*. 1998;13:624–628.
7. Roach ES, DiMario FJ, Kandt RS, Northrup H. Tuberous sclerosis consensus conference: recommendations for diagnostic evaluation. *J Child Neurol*. 1999;14:401–407.
8. Krueger DA, Northrup H. Tuberous sclerosis complex surveillance and management: recommendations of the 2012 international tuberous sclerosis complex consensus conference. *Pediatr Neurol*. 2013;49:255–265.
9. National Comprehensive Cancer Network. Development and update of guidelines. Available at: <https://www.nccn.org/guidelines/guidelines-process/development-and-update-of-guidelines>. Accessed August 3, 2021.
10. Davis PE, Filip-Dhima R, Sideridis G, et al. Presentation and diagnosis of tuberous sclerosis complex in infants. *Pediatrics*. 2017;140:e20164040.
11. Kingswood JC, d'Augeres GB, Belousova E, et al. Tuberous Sclerosis registry to increase disease awareness (TOSCA) - baseline data on 2093 patients. *Orphanet J Rare Dis*. 2017;12:2.
12. Richards S, Aziz N, Bale S, et al. Standards and guidelines for the interpretation of sequence variants: a joint consensus recommendation of the American College of Medical Genetics and Genomics and the Association for Molecular Pathology. *Genet Med*. 2015;17:405–424.
13. Dufner Almeida LG, Nanhoe S, Zonta A, et al. Comparison of the functional and structural characteristics of rare TSC2 variants with clinical and genetic findings. *Hum Mutat*. 2020;41:759–773.
14. Hoogveen-Westerveld M, Ekong R, Povey S, et al. Functional assessment of TSC1 missense variants identified in individuals with tuberous sclerosis complex. *Hum Mutat*. 2012;33:476–479.
15. Hoogveen-Westerveld M, Ekong R, Povey S, et al. Functional assessment of TSC2 variants identified in individuals with tuberous sclerosis complex. *Hum Mutat*. 2013;34:167–175.
16. Hoogveen-Westerveld M, Wentink M, van den Heuvel D, et al. Functional assessment of variants in the TSC1 and TSC2 genes identified in individuals with tuberous sclerosis complex. *Hum Mutat*. 2011;32:424–435.
17. Tyburczy ME, Dies KA, Glass J, et al. Mosaic and intronic mutations in TSC1/TSC2 explain the majority of TSC patients with no mutation identified by conventional testing. *PLoS Genet*. 2015;11:e1005637.
18. Giannikou K, Lasseter KD, Grevelink JM, et al. Low-level mosaicism in tuberous sclerosis complex: prevalence, clinical features, and risk of disease transmission. *Genet Med*. 2019;21:2639–2643.
19. Peron A, Au KS, Northrup H. Genetics, genomics, and genotype-phenotype correlations of TSC: insights for clinical practice. *Am J Med Genet C Semin Med Genet*. 2018;178:281–290.
20. Boronat S, Barber I, Pargaonkar V, Chang J, Thiele EA. Sclerotic bone lesions at abdominal magnetic resonance imaging in children with tuberous sclerosis complex. *Pediatr Radiol*. 2016;46:689–694.
21. Boronat S, Barber I, Thiele EA. Sclerotic bone lesions in tuberous sclerosis complex: a genotype-phenotype study. *Am J Med Genet A*. 2017;173:1891–1895.

22. Brakemeier S, Vogt L, Adams LC, et al. Sclerotic bone lesions as a potential imaging biomarker for the diagnosis of tuberous sclerosis complex. *Sci Rep.* 2018;8:953.
23. Inoue Y, Nemoto Y, Murata R, et al. CT and MR imaging of cerebral tuberous sclerosis. *Brain Dev.* 1998;20:209–221.
24. Kalantari BN, Salamon N. Neuroimaging of tuberous sclerosis: spectrum of pathologic findings and frontiers in imaging. *Am J Roentgenol.* 2008;190:W304–W309.
25. Golec W, Jakimów-Kostrzewa A, Mruk B, Józwiak S. Role of gadolinium-based contrast agents in neurological disorders. *Neurol Neurochir Pol.* 2020;54:399–409.
26. Lee JY, Park JE, Kim HS, et al. Up to 52 administrations of macrocyclic ionic MR contrast agent are not associated with intracranial gadolinium deposition: multifactorial analysis in 385 patients. *PLoS One.* 2017;12:e0183916.
27. Radbruch A, Richter H, Fingerhut S, et al. Gadolinium deposition in the brain in a large animal model: comparison of linear and macrocyclic gadolinium-based contrast agents. *Invest Radiol.* 2019;54:531–536.
28. Gulani V, Calamante F, Shellock FG, Kanal E, Reeder SB. Gadolinium deposition in the brain: summary of evidence and recommendations. *Lancet Neurol.* 2017;16:564–570.
29. De Ridder J, Verhelle B, Vervisch J, et al. Early epileptiform EEG activity in infants with tuberous sclerosis complex predicts epilepsy and neurodevelopmental outcomes. *Epilepsia.* 2021;62:1208–1219.
30. Wu JY, Goyal M, Peters JM, et al. Scalp EEG spikes predict impending epilepsy in TSC infants: a longitudinal observational study. *Epilepsia.* 2019;60:2428–2436.
31. Bombardieri R, Pinci M, Moavero R, Cerminara C, Curatolo P. Early control of seizures improves long-term outcome in children with tuberous sclerosis complex. *Eur J Paediatr Neurol.* 2010;14:146–149.
32. Chu-Shore CJ, Major P, Camposano S, Muzykewicz D, Thiele EA. The natural history of epilepsy in tuberous sclerosis complex. *Epilepsia.* 2010;51:1236–1241.
33. Józwiak S, Kotulska K, Domańska-Pakiela D, et al. Antiepileptic treatment before the onset of seizures reduces epilepsy severity and risk of mental retardation in infants with tuberous sclerosis complex. *Eur J Paediatr Neurol.* 2011;15:424–431.
34. Kotulska K, Kwiatkowski DJ, Curatolo P, et al. Prevention of epilepsy in infants with tuberous sclerosis complex in the EPISTOP trial. *Ann Neurol.* 2021;89:304–314.
35. Moavero R, Kotulska K, Lagae L, et al. Is autism driven by epilepsy in infants with tuberous sclerosis complex? *Ann Clin Transl Neurol.* 2020;7:1371–1381.
36. Ho CN, Rushing G, Valentine JE, Rosbeck KL, Roberds SL. The voice of the patient: a report from the tuberous sclerosis alliance externally-led patient-focused drug development meeting. 2018.
37. de Vries PJ, Whittemore VH, Leclézio L, et al. Tuberous sclerosis associated neuropsychiatric disorders (TAND) and the TAND Checklist. *Pediatr Neurol.* 2015;52:25–35.
38. Leclézio L, Jansen A, Whittemore VH, de Vries PJ. Pilot validation of the tuberous sclerosis-associated neuropsychiatric disorders (TAND) checklist. *Pediatr Neurol.* 2015;52:16–24.
39. De Vries P, Humphrey A, McCartney D, et al. Consensus clinical guidelines for the assessment of cognitive and behavioural problems in tuberous sclerosis. *Eur Child Adolesc Psychiatry.* 2005;14:183–190.
40. Graffigna G, Bosio C, Cecchini I. Assisting a child with tuberous sclerosis complex (TSC): a qualitative deep analysis of parents' experience and caring needs. *BMJ Open.* 2013;3:e003707.
41. Jansen AC, Vanclooster S, de Vries PJ, et al. Burden of illness and quality of life in tuberous sclerosis complex: findings from the TOSCA study. *Front Neurol.* 2020;11:904.
42. Patel U, Simpson E, Kingswood JC, Saggari-Malik AK. Tuberous sclerosis complex: analysis of growth rates aids differentiation of renal cell carcinoma from atypical or minimal-fat-containing angiomyolipoma. *Clin Radiol.* 2005;60:665–673.
43. Halpenny D, Snow A, McNeill G, Torreggiani WC. The radiological diagnosis and treatment of renal angiomyolipoma-current status. *Clin Radiol.* 2010;65:99–108.
44. Davenport MS, Perazella MA, Yee J, et al. Use of intravenous iodinated contrast media in patients with kidney disease: consensus statements from the American College of Radiology and the National Kidney Foundation. *Radiology.* 2020;294:660–668.
45. Gilligan LA, Davenport MS, Trout AT, et al. Risk of acute kidney injury following contrast-enhanced CT in hospitalized pediatric patients: a propensity score analysis. *Radiology.* 2020;294:548–556.
46. Hinson JS, Ehmman MR, Fine DM, et al. Risk of acute kidney injury after intravenous contrast media administration. *Ann Emerg Med.* 2017;69:577–586.e4.
47. Kingswood C, Bolton P, Crawford P, et al. The clinical profile of tuberous sclerosis complex (TSC) in the United Kingdom: a retrospective cohort study in the Clinical Practice Research Datalink (CPRD). *Eur J Paediatr Neurol.* 2015;20:296–308.
48. Kingswood JC, Belousova E, Benedik MP, et al. Renal manifestations of tuberous sclerosis complex: key findings from the final analysis of the TOSCA study focussing mainly on renal angiomyolipomas. *Front Neurol.* 2020;11:972.
49. Kingswood JC, Belousova E, Benedik MP, et al. Renal angiomyolipoma in patients with tuberous sclerosis complex: findings from the Tuberous Sclerosis registry to increase disease awareness. *Nephrol Dial Transplant.* 2019;34:502–508.
50. Levey AS, Bosch JP, Lewis JB, Greene T, Rogers N, Roth D. A more accurate method to estimate glomerular filtration rate from serum creatinine: a new prediction equation. Modification of Diet in Renal Disease Study Group. *Ann Intern Med.* 1999;130:461–470.
51. Levey AS, Stevens LA, Schmid CH, et al. A new equation to estimate glomerular filtration rate. *Ann Intern Med.* 2009;150:604–612.
52. Nehus EJ, Laskin BL, Kathman TI, Bissler JJ. Performance of cystatin C-based equations in a pediatric cohort at high risk of kidney injury. *Pediatr Nephrol.* 2013;28:453–461.
53. Schwartz GJ, Muñoz A, Schneider MF, et al. New equations to estimate GFR in children with CKD. *J Am Soc Nephrol.* 2009;20:629–637.
54. Inker LA, Schmid CH, Tighiouart H, et al. Estimating glomerular filtration rate from serum creatinine and cystatin C. *N Engl J Med.* 2012;367:20–29.
55. Tækker M, Kristjándóttir B, Graumann O, Laursen CB, Pietersen PI. Diagnostic accuracy of low-dose and ultra-low-dose CT in detection of chest pathology: a systematic review. *Clin Imaging.* 2021;74:139–148.
56. McCormack FX. Lymphangioleiomyomatosis: a clinical update. *Chest.* 2008;133:507–516.
57. Ghonge NP, Chowdhury V. Minimum-intensity projection images in high-resolution computed tomography lung: technology update. *Lung India.* 2018;35:439–440.
58. Young LR, Inoue Y, McCormack FX. Diagnostic potential of serum VEGF-D for lymphangioleiomyomatosis. *N Engl J Med.* 2008;358:199–200.
59. Young LR, VanDyke R, Gulleman PM, et al. Serum vascular endothelial growth factor-D prospectively distinguishes lymphangioleiomyomatosis from other diseases. *Chest.* 2010;138:674–681.
60. Tian X, Glass JE, Kwiatkowski DJ, et al. Lymphangioleiomyomatosis association with underlying genotype in patients with tuberous sclerosis complex. *Ann Am Thorac Soc.* 2021;18:815–819.
61. Muir TE, Leslie KO, Popper H, et al. Micronodular pneumocyte hyperplasia. *Am J Surg Pathol.* 1998;22:465–472.
62. Muzykewicz DA, Black ME, Muse V, et al. Multifocal micronodular pneumocyte hyperplasia: computed tomographic appearance and follow-up in tuberous sclerosis complex. *J Comput Assist Tomogr.* 2012;36:518–522.
63. Tyburczy ME, Wang JA, Li S, et al. Sun exposure causes somatic second-hit mutations and angiofibroma development in tuberous sclerosis complex. *Hum Mol Genet.* 2014;23:2023–2029.
64. Teng JM, Cowen EW, Wataya-Kaneda M, et al. Dermatologic and dental aspects of the 2012 international tuberous sclerosis complex consensus statements. *JAMA Dermatol.* 2014;150:1095–1101.
65. Gosnell ES, Krueger D, Ruck P, Buff-Lindner AH, Horn PS, Griffith M. Oral manifestations and quality of life in children with tuberous sclerosis complex: a descriptive study. *Pediatr Dent.* 2021;43:140–144.
66. Mlynarczyk G. Enamel pitting. A common sign of tuberous sclerosis. *Ann N Y Acad Sci.* 1991;615:367–369.
67. Lygidakis NA, Lindenbaum RH. Pitted enamel hypoplasia in tuberous sclerosis patients and first-degree relatives. *Clin Genet.* 1987;32:216–221.
68. Hinton RB, Prakash A, Romp RL, Krueger DA, Knilans TK. Cardiovascular manifestations of tuberous sclerosis complex and summary of the revised diagnostic criteria and surveillance and management recommendations from the international tuberous sclerosis consensus group. *J Am Heart Assoc.* 2014;3:e001493.
69. Aronow M, Nakagawa J, Gupta A, Traboulsi E, Singh A. Tuberous sclerosis complex: genotype/phenotype correlation of retinal findings. *Ophthalmology.* 2012;119:1917–1923.
70. Salerno AE, Marsenic O, Meyers KEC, Kaplan BS, Hellinger JC. Vascular involvement in tuberous sclerosis. *Pediatr Nephrol.* 2010;25:7?tlj?tlj1555–1561.
71. Cinalli G, Imperato A, Mirone G, et al. Initial experience with endoscopic ultrasonic aspirator in purely neuroendoscopic removal of intraventricular tumors. *J Neurosurg Pediatr.* 2017;19:325–332.
72. Fohlen M, Ferrand-Sorbets S, Delalande O, Dorfmüller G. Surgery for subependymal giant cell astrocytomas in children with tuberous sclerosis complex. *Childs Nerv Syst.* 2018;34:1511–1519.
73. Rodgers SD, Bassani L, Weiner HL, Harter DH. Stereotactic endoscopic resection and surgical management of a subependymal giant cell astrocytoma: case report. *J Neurosurg Pediatr.* 2012;9:417–420.
74. Dadey DY, Kamath AA, Leuthardt EC, Smyth MD. Laser interstitial thermal therapy for subependymal giant cell astrocytoma: technical case report. *Neurosurg Focus.* 2016;41:E9.
75. Karsy M, Patel DM, Bollo RJ. Trapped ventricle after laser ablation of a subependymal giant cell astrocytoma complicated by intraventricular gadolinium extravasation: case report. *J Neurosurg Pediatr.* 2018;21:523–527.
76. Harter DH, Bassani L, Rodgers SD, et al. A management strategy for intraventricular subependymal giant cell astrocytomas in tuberous sclerosis complex. *J Neurosurg Pediatr.* 2014;13:21–28.
77. Kotulska K, Borkowska J, Roszkowski M, et al. Surgical treatment of subependymal giant cell astrocytoma in tuberous sclerosis complex patients. *Pediatr Neurol.* 2014;50:307–312.
78. Roth J, Roach ES, Bartels U, et al. Subependymal giant cell astrocytoma: diagnosis, screening, and treatment. Recommendations from the

- International Tuberous Sclerosis Complex Consensus Conference 2012. *Pediatr Neurol.* 2013;49:439–444.
79. Jiang T, Du J, Raynald, Wang J, Li C. Presurgical administration of mTOR inhibitors in patients with large subependymal giant cell astrocytoma associated with tuberous sclerosis complex. *World Neurosurg.* 2017;107:1053.e1–1053.e6.
 80. Arroyo MS, Krueger DA, Broomall E, Stevenson CB, Franz DN. Acute management of symptomatic subependymal giant cell astrocytoma with everolimus. *Pediatr Neurol.* 2017;72:81–85.
 81. Moavero R, Carai A, Mastronuzzi A, et al. Everolimus alleviates obstructive hydrocephalus due to subependymal giant cell astrocytomas. *Pediatr Neurol.* 2017;68:59–63.
 82. Franz D, Belousova E, Sparagana S, et al. Efficacy and safety of everolimus for subependymal giant cell astrocytomas associated with tuberous sclerosis complex (EXIST-1): a multicentre, randomised, placebo-controlled phase 3 trial. *Lancet.* 2012;381:125–132.
 83. French JA, Lawson JA, Yapici Z, et al. Adjunctive everolimus therapy for treatment-resistant focal-onset seizures associated with tuberous sclerosis (EXIST-3): a phase 3, randomised, double-blind, placebo-controlled study. *Lancet.* 2016;388:2153–2163.
 84. Bissler JJ, Kingswood JC, Radzikowska E, et al. Everolimus for angiomyolipoma associated with tuberous sclerosis complex or sporadic lymphangiomyomatosis (EXIST-2): a multicentre, randomised, double-blind, placebo-controlled trial. *Lancet.* 2013;381:817–824.
 85. Franz DN, Agricola K, Mays M, et al. Everolimus for subependymal giant cell astrocytoma: 5-year final analysis. *Ann Neurol.* 2015;78:929–938.
 86. Franz DN, Belousova E, Sparagana S, et al. Long-term use of everolimus in patients with tuberous sclerosis complex: final results from the EXIST-1 study. *PLoS One.* 2016;11:e0158476.
 87. Curatolo P, Bjornvold M, Dill PE, et al. The role of mTOR inhibitors in the treatment of patients with tuberous sclerosis complex: evidence-based and expert opinions. *Drugs.* 2016;76:551–565.
 88. Habib SL, Al-Obaidi NY, Nowacki M, et al. Is mTOR inhibitor good enough for treatment all tumors in TSC patients? *J Cancer.* 2016;7:1621–1631.
 89. Weidman DR, Pole JD, Bouffet E, Taylor MD, Bartels U. Dose-level response rates of mTOR inhibition in tuberous sclerosis complex (TSC) related subependymal giant cell astrocytoma (SEGA). *Pediatr Blood Cancer.* 2015;62:1754–1760.
 90. Trelinska J, Dachowska I, Baranska D, et al. Maintenance therapy with everolimus for subependymal giant cell astrocytoma in patients with tuberous sclerosis (the EMINENTS study). *Pediatr Blood Cancer.* 2017;64:e26347.
 91. Jozwiak S, Kotulska K, Berkowitz N, Brechenmacher T, Franz DN. Safety of everolimus in patients younger than 3 years of age: results from EXIST-1, a randomized, controlled clinical trial. *J Pediatr.* 2016;172:151–155.e1.
 92. Saffari A, Brosse I, Wiemer-Kruel A, et al. Safety and efficacy of mTOR inhibitor treatment in patients with tuberous sclerosis complex under 2 years of age - a multicenter retrospective study. *Orphanet J Rare Dis.* 2019;14:96.
 93. Krueger DA, Capal JK, Curatolo P, et al. Short-term safety of mTOR inhibitors in infants and very young children with tuberous sclerosis complex (TSC): multicenter clinical experience. *Eur J Paediatr Neurol.* 2018;22:1066–1073.
 94. de Ribauxpierre S, Dorfmueller G, Bultheau C, et al. Subependymal giant-cell astrocytomas in pediatric tuberous sclerosis disease: when should we operate? *Neurosurgery.* 2007;60:83–89. discussion 89–90.
 95. Jansen AC, Belousova E, Benedik MP, et al. Clinical characteristics of subependymal giant cell astrocytoma in tuberous sclerosis complex. *Front Neurol.* 2019;10:705.
 96. Jansen AC, Belousova E, Benedik MP, et al. Newly diagnosed and growing subependymal giant cell astrocytoma in adults with tuberous sclerosis complex: results from the international TOSCA study. *Front Neurol.* 2019;10:821.
 97. Capal JK, Bernardino-Cuesta B, Horn PS, et al. Influence of seizures on early development in tuberous sclerosis complex. *Epilepsy Behav.* 2017;70:245–252.
 98. Moavero R, Benvenuto A, Gialloreti LE, et al. Early clinical predictors of autism spectrum disorder in infants with tuberous sclerosis complex: results from the EPiSTOP study. *J Clin Med.* 2019;8:788.
 99. Camposano SE, Major P, Halpern E, Thiele EA. Vigabatrin in the treatment of childhood epilepsy: a retrospective chart review of efficacy and safety profile. *Epilepsia.* 2008;49:1186–1191.
 100. Parisi P, Bombardieri R, Curatolo P. Current role of vigabatrin in infantile spasms. *Eur J Paediatr Neurol.* 2007;11:331–336.
 101. Hussain SA, Tsao J, Li M, et al. Risk of vigabatrin-associated brain abnormalities on MRI in the treatment of infantile spasms is dose-dependent. *Epilepsia.* 2017;58:674–682.
 102. Rodrigues C, Chiron C, Ounissi M, et al. Pharmacokinetic evaluation of vigabatrin dose for the treatment of refractory focal seizures in children using adult and pediatric data. *Epilepsy Res.* 2019;150:38–45.
 103. Elterman RD, Shields WD, Mansfield KA, Nakagawa J. Randomized trial of vigabatrin in patients with infantile spasms. *Neurology.* 2001;57:1416–1421.
 104. Hussain SA, Schmid E, Peters JM, et al. High vigabatrin dosage is associated with lower risk of infantile spasms relapse among children with tuberous sclerosis complex. *Epilepsy Res.* 2018;148:1–7.
 105. O'Callaghan FJ, Edwards SW, Alber FD, et al. Safety and effectiveness of hormonal treatment versus hormonal treatment with vigabatrin for infantile spasms (ICISS): a randomised, multicentre, open-label trial. *Lancet Neurol.* 2017;16:33–42.
 106. Thiele EA, Bebin EM, Bhathal H, et al. Add-on cannabidiol treatment for drug-resistant seizures in tuberous sclerosis complex: a placebo-controlled randomized clinical trial. *JAMA Neurol.* 2021;78:285–292.
 107. Franz DN, Lawson JA, Yapici Z, et al. Everolimus dosing recommendations for tuberous sclerosis complex-associated refractory seizures. *Epilepsia.* 2018;59:1188–1197.
 108. Gilmartin CGS, Dowd Z, Parker APJ, Harijan P. Interaction of cannabidiol with other antiseizure medications: a narrative review. *Seizure.* 2021;86:189–196.
 109. Ebrahimi-Fakhari D, Agricola KD, Tudor C, Krueger D, Franz DN. Cannabidiol elevates mechanistic target of rapamycin inhibitor levels in patients with tuberous sclerosis complex. *Pediatr Neurol.* 2020;105:59–61.
 110. Wiemer-Kruel A, Stiller B, Bast T. Cannabidiol interacts significantly with everolimus-report of a patient with tuberous sclerosis complex. *Neuropediatrics.* 2019;50:400–403.
 111. Kossoff EH, Thiele EA, Pfeifer HH, McGrogan JR, Freeman JM. Tuberous sclerosis complex and the ketogenic diet. *Epilepsia.* 2005;46:1684–1686.
 112. Park S, Lee EJ, Eom S, Kang HC, Lee JS, Kim HD. Ketogenic diet for the management of epilepsy associated with tuberous sclerosis complex in children. *J Epilepsy Res.* 2017;7:45–49.
 113. Larson AM, Pfeifer HH, Thiele EA. Low glycemic index treatment for epilepsy in tuberous sclerosis complex. *Epilepsy Res.* 2012;99:180–182.
 114. Fallah A, Rodgers SD, Weil AG, et al. Resective epilepsy surgery for tuberous sclerosis in children: determining predictors of seizure outcomes in a multicenter retrospective cohort study. *Neurosurgery.* 2015;77:517–524. discussion 524.
 115. Liu S, Yu T, Guan Y, et al. Resective epilepsy surgery in tuberous sclerosis complex: a nationwide multicenter retrospective study from China. *Brain.* 2020;143:570–581.
 116. Vannicola C, Tassi L, Barba C, et al. Seizure outcome after epilepsy surgery in tuberous sclerosis complex: results and analysis of predictors from a multicenter study. *J Neurol Sci.* 2021;427:117506.
 117. Grayson LE, Peters JM, McPherson T, et al. Pilot study of neurodevelopmental impact of early epilepsy surgery in tuberous sclerosis complex. *Pediatr Neurol.* 2020;109:39–46.
 118. Treiber JM, Curry DJ, Weiner HL, Roth J. Epilepsy surgery in tuberous sclerosis complex (TSC): emerging techniques and redefinition of treatment goals. *Childs Nerv Syst.* 2020;36:2519–2525.
 119. Grioni D, Landi A. Does vagal nerve stimulation treat drug-resistant epilepsy in patients with tuberous sclerosis complex? *World Neurosurg.* 2019;121:251–253.
 120. McDermott DS, Mirro EA, Fetrow K, et al. Brain-responsive neurostimulation for the treatment of adults with epilepsy in tuberous sclerosis complex: a case series. *Epilepsia Open.* 2021;6:419–424.
 121. de Vries PJ, Wilde L, de Vries MC, Moavero R, Pearson DA, Curatolo P. A clinical update on tuberous sclerosis complex-associated neuropsychiatric disorders (TAND). *Am J Med Genet C Semin Med Genet.* 2018;178:?:tjlm ?tj1309–320.
 122. de Vries PJ, Belousova E, Benedik MP, et al. Tuberous sclerosis complex-associated neuropsychiatric disorders (TAND): new findings on age, sex, and genotype in relation to intellectual phenotype. *Front Neurol.* 2020;11:603.
 123. de Vries PJ, Belousova E, Benedik MP, et al. TSC-associated neuropsychiatric disorders (TAND): findings from the TOSCA natural history study. *Orphanet J Rare Dis.* 2018;13:157.
 124. Bissler JJ, Budde K, Sauter M, et al. Effect of everolimus on renal function in patients with tuberous sclerosis complex: evidence from EXIST-1 and EXIST-2. *Nephrol Dial Transplant.* 2019;34:1000–1008.
 125. Bissler JJ, Kingswood JC, Radzikowska E, et al. Everolimus long-term use in patients with tuberous sclerosis complex: four-year update of the EXIST-2 study. *PLoS One.* 2017;12:e0180939.
 126. Zonnenberg BA, Neary MP, Duh MS, Ionescu-Iltu R, Fortier J, Vekeman F. Observational study of characteristics and clinical outcomes of Dutch patients with tuberous sclerosis complex and renal angiomyolipoma treated with everolimus. *PLoS One.* 2018;13:e0204646.
 127. Wei CC, Tsai JD, Sheu JN, et al. Continuous low-dose everolimus shrinkage tuberous sclerosis complex-associated renal angiomyolipoma: a 48-month follow-up study. *J Investig Med.* 2019;67:686–690.
 128. Davies M, Saxena A, Kingswood JC. Management of everolimus-associated adverse events in patients with tuberous sclerosis complex: a practical guide. *Orphanet J Rare Dis.* 2017;12:35.
 129. National high blood pressure education program working group on high blood pressure in children and Adolescents. The fourth report on the diagnosis, evaluation, and treatment of high blood pressure in children and adolescents. *Pediatrics.* 2004;114:555–576.
 130. Bissler JJ, Christopher Kingswood J. Renal manifestation of tuberous sclerosis complex. *Am J Med Genet C Semin Med Genet.* 2018;178:338–347.
 131. Siroky BJ, Yin H, Dixon BP, et al. Evidence for pericyte origin of TSC-associated renal angiomyolipomas and implications for angiotensin receptor inhibition therapy. *Am J Physiol Renal Physiol.* 2014;307:?:tjlm ?tj1F560–F570.

132. Vabret E, Couchoud C, Lassalle M, Vigneau C. From tuberous sclerosis complex to end stage renal disease: who are these patients? *J Nephrol.* 2021;34:607–615.
133. Jimenez RE, Eble JN, Reuter VE, et al. Concurrent angiomyolipoma and renal cell neoplasia: a study of 36 cases. *Mod Pathol.* 2001;14:157–163.
134. Henske EP. The genetic basis of kidney cancer: why is tuberous sclerosis complex often overlooked? *Curr Mol Med.* 2004;4:825–831.
135. Lemaître L, Claudon M, Dubrulle F, Mazeman E. Imaging of angiomyolipomas. *Semin Ultrasound CT MR.* 1997;18:100–114.
136. Bissler JJ, Racadio J, Donnelly LF, Johnson ND. Reduction of postembolization syndrome after ablation of renal angiomyolipoma. *Am J Kidney Dis.* 2002;39:966–971.
137. Mourikis D, Chatziioannou A, Antoniou A, Kehagias D, Gikas D, Vlahos L. Selective arterial embolization in the management of symptomatic renal angiomyolipomas. *Eur J Radiol.* 1999;32:153–159.
138. Mehta V, Venkataraman G, Antic T, Rubinas TC, Le Poole IC, Picken MM. Renal angiomyolipoma, fat-poor variant—a clinicopathologic mimicker of malignancy. *Virchows Arch.* 2013;463:41–46.
139. Hu-Wang E, Schuzer JL, Rollison S, et al. Chest CT scan at radiation dose of a posteroanterior and lateral chest radiograph series: a proof of principle in lymphangioleiomyomatosis. *Chest.* 2019;155:528–533.
140. McCormack FX, Gupta N, Finlay GR, et al. Official American Thoracic Society/Japanese Respiratory Society clinical practice guidelines: lymphangioleiomyomatosis diagnosis and management. *Am J Respir Crit Care Med.* 2016;194:748–761.
141. Goldberg HJ, Harari S, Cottin V, et al. Everolimus for the treatment of lymphangioleiomyomatosis: a phase II study. *Eur Respir J.* 2015;46:783–794.
142. Johnson SR, Tattersfield AE. Clinical experience of lymphangioleiomyomatosis in the UK. *Thorax.* 2000;55:1052–1057.
143. Cohen MM, Freyer AM, Johnson SR. Pregnancy experiences among women with lymphangioleiomyomatosis. *Respir Med.* 2009;103:766–772.
144. Hayashida M, Yasuo M, Hanaoka M, et al. Reductions in pulmonary function detected in patients with lymphangioleiomyomatosis: an analysis of the Japanese National Research Project on Intractable Diseases database. *Respir Investig.* 2016;54:193–200.
145. Urban T, Lazor R, Lacroque J, et al. Pulmonary lymphangioleiomyomatosis. A study of 69 patients. Groupe d'Etudes et de Recherche sur les Maladies "Orphelines" Pulmonaires (GERM"O"P). *Medicine (Baltimore).* 1999;78:321–337.
146. Gupta N, Finlay GA, Kotloff RM, et al. Lymphangioleiomyomatosis diagnosis and management: high-resolution chest computed tomography, transbronchial lung biopsy, and pleural disease management. An Official American Thoracic Society/Japanese Respiratory Society clinical practice guideline. *Am J Respir Crit Care Med.* 2017;196:1337–1348.
147. Khawar MU, Yazdani D, Zhu Z, Jandarov R, Dilling DF, Gupta N. Clinical outcomes and survival following lung transplantation in patients with lymphangioleiomyomatosis. *J Heart Lung Transplant.* 2019;38:949–955.
148. Dabora SL, Franz DN, Ashwal S, et al. Multicenter phase 2 trial of sirolimus for tuberous sclerosis: kidney angiomyolipomas and other tumors regress and VEGF-D levels decrease. *PLoS One.* 2011;6:e23379.
149. Franz DN, Budde K, Kingswood JC, et al. Effect of everolimus on skin lesions in patients treated for subependymal giant cell astrocytoma and renal angiomyolipoma: final 4-year results from the randomized EXIST-1 and EXIST-2 studies. *J Eur Acad Dermatol Venereol.* 2018;32:1796–1803.
150. Nathan N, Wang JA, Li S, et al. Improvement of tuberous sclerosis complex (TSC) skin tumors during long-term treatment with oral sirolimus. *J Am Acad Dermatol.* 2015;73:802–808.
151. Koenig MK, Bell CS, Hebert AA, et al. Efficacy and safety of topical rapamycin in patients with facial angiofibromas secondary to tuberous sclerosis complex: the TREATMENT randomized clinical trial. *JAMA Dermatol.* 2018;154:773–780.
152. Wataya-Kaneda M, Ohno Y, Fujita Y, et al. Sirolimus gel treatment vs placebo for facial angiofibromas in patients with tuberous sclerosis complex: a randomized clinical trial. *JAMA Dermatol.* 2018;154:781–788.
153. Malissen N, Vergely L, Simon M, Roubertie A, Malinge MC, Bessis D. Long-term treatment of cutaneous manifestations of tuberous sclerosis complex with topical 1% sirolimus cream: a prospective study of 25 patients. *J Am Acad Dermatol.* 2017;77:464–472.e3.
154. Wataya-Kaneda M, Nagai H, Ohno Y, et al. Safety and efficacy of the sirolimus gel for TSC patients with facial skin lesions in a long-term, open-label, extension, uncontrolled clinical trial. *Dermatol Ther (Heidelb).* 2020;10:635–650.
155. Wataya-Kaneda M, Tanaka M, Yang L, et al. Clinical and histologic analysis of the efficacy of topical rapamycin therapy against hypomelanotic macules in tuberous sclerosis complex. *JAMA Dermatol.* 2015;151:722–730.
156. Dickinson SE, Janda J, Criswell J, et al. Inhibition of Akt enhances the chemopreventive effects of topical rapamycin in mouse skin. *Cancer Prev Res (Phila).* 2016;9:215–224.
157. Fioramonti P, De Santo L, Ruggieri M, et al. Co2/Erbium:YAG/Dye laser combination: an effective and successful treatment for angiofibromas in tuberous sclerosis. *Aesthetic Plast Surg.* 2014;38:192–198.
158. Ali FR, Mallipeddi R, Craythorne EE, Sheth N, Al-Niaimi F. Our experience of carbon dioxide laser ablation of angiofibromas: case series and literature review. *J Cosmet Laser Ther.* 2016;18:372–375.
159. American Academy of Pediatric Dentistry. Periodicity of examination, preventive dental services, anticipatory guidance/counseling, and oral treatment for infants, children, and adolescents. In: Reference Manual of Pediatric Dentistry. Chicago, IL: American Academy of Pediatric Dentistry; 2020:232–242.
160. Zhang ZQ, Shen C, Long Q, et al. Sirolimus for retinal astrocytic hamartoma associated with tuberous sclerosis complex. *Ophthalmology.* 2015;122:1947–1949.
161. Nallasamy N, Seider MI, Gururangan S, Mruthyunjaya P. Everolimus to treat aggressive retinal astrocytic hamartoma in tuberous sclerosis complex. *J AAPOS.* 2017;21:328–331.
162. Mennel S, Meyer CH, Peter S, Schmidt JC, Kroll P. Current treatment modalities for exudative retinal hamartomas secondary to tuberous sclerosis: review of the literature. *Acta Ophthalmol Scand.* 2007;85:127–132.
163. Longi M, Gold AS, Murray TG. Combined bevacizumab and triamcinolone acetonide injections for macular edema in a patient with astrocytic hamartomas and tuberous sclerosis. *Ophthalmic Surg Lasers Imaging Retina.* 2013;44:85–90.
164. Hardus P, Verduin WM, Engelsman M, et al. Visual field loss associated with vigabatrin: quantification and relation to dosage. *Epilepsia.* 2001;42:262–267.
165. Malmgren K, Ben-Menachem E, Frisén L. Vigabatrin visual toxicity: evolution and dose dependence. *Epilepsia.* 2001;42:609–615.
166. American Association of Pediatric Ophthalmology. Vigabatrin: the problem of monitoring for peripheral vision loss in children. Available at: <https://aaop.org/viewdocument/vigabatrin-the-problem-of-monitoring>; 2017.
167. Mowrey K, Northrup H, Rougeau P, et al. Frequency, progression, and current management: report of 16 new cases of nonfunctional pancreatic neuroendocrine tumors in tuberous sclerosis complex and comparison with previous reports. *Front Neurol.* 2021;12:627672.
168. Mehta S, Rusyn L, Ginsburg H, Hajdu C, Kohn B. Pancreatic neuroendocrine tumor in a young child with tuberous sclerosis complex 1. *J Endocr Soc.* 2019;3:1201–1206.
169. Kalkan E, Waguespack SG. Endocrine tumors associated with neurofibromatosis type 1, Peutz-Jeghers syndrome and other familial neoplasia syndromes. *Front Horm Res.* 2013;41:166–181.
170. Lodish MB, Stratakis CA. Endocrine tumours in neurofibromatosis type 1, tuberous sclerosis and related syndromes. *Best Pract Res Clin Endocrinol Metab.* 2010;24:439–449.
171. Wataya-Kaneda M, Tanaka M, Hamasaki T, Katayama I. Trends in the prevalence of tuberous sclerosis complex manifestations: an epidemiological study of 166 Japanese patients. *PLoS One.* 2013;8:e63910.
172. Auladell M, Boronat S, Barber I, Thiele EA. Thyroid nodules on chest CT of patients with tuberous sclerosis complex. *Am J Med Genet A.* 2015;167a:2992–2997.
173. US Food and Drug Administration. Drug development and drug interactions: table of substrates, inhibitors, and inducers. Available at: <https://www.fda.gov/drugs/drug-interactions-labeling/drug-development-and-drug-interactions-table-substrates-inhibitors-and-inducers>; 2020. Accessed June 29, 2021.
174. Agricola K, Tudor C, Krueger D, Neal D. Nursing implications for the lifelong management of tuberous sclerosis complex. *J Neurosci Nurs.* 2013;45:223–239.
175. Kaplan B, Qazi Y, Wellen JR. Strategies for the management of adverse events associated with mTOR inhibitors. *Transpl Rev (Orlando).* 2014;28:126–133.
176. Braun M, Young J, Reiner CS, et al. Low-dose oral sirolimus and the risk of menstrual-cycle disturbances and ovarian cysts: analysis of the randomized controlled SUISSSE ADPKD trial. *PLoS One.* 2012;7:e45868.
177. Bachmann F, Glander P, Budde K, Bachmann C. High incidence of ovarian cysts in women receiving mTOR inhibitors after renal transplantation. *J Womens Health (Larchmt).* 2018;27:394–398.
178. Bobeff K, Krajewska K, Baranska D, et al. Maintenance therapy with everolimus for subependymal giant cell astrocytoma in patients with tuberous sclerosis - final results from the EMINENTS study. *Front Neurol.* 2021;12:581102.
179. de Vries PJ, Leclézio L, Wilmschurst JM, et al. Diagnosis, monitoring and treatment of tuberous sclerosis complex: a South African consensus response to international guidelines. *S Afr Med J.* 2017;107:368–478.
180. Lawson JA, Chan CF, Chi CS, et al. Managing tuberous sclerosis in the Asia-Pacific region: refining practice and the role of targeted therapy. *J Clin Neurosci.* 2014;21:1180–1187.
181. Macaya A, Torra R. Recommendations for the multidisciplinary management of tuberous sclerosis complex. *Med Clin (Barc).* 2016;147:211–216.
182. Bar C, Gobeira R, Azzi R, et al. Experience of follow-up, quality of life, and transition from pediatric to adult healthcare of patients with tuberous sclerosis complex. *Epilepsy Behav.* 2019;96:23–27.
183. Nabbout R, Teng T, Chemaly N, Breuillard D, Kuchenbuch M. Transition of patients with childhood onset epilepsy: perspectives from pediatric and adult neurologists. *Epilepsy Behav.* 2020;104:106889.

184. Both P, Ten Holt L, Mous S, et al. Tuberous sclerosis complex: concerns and needs of patients and parents from the transitional period to adulthood. *Epilepsy Behav.* 2018;83:13–21.
185. Peron A, Canevini MP, Ghelma F, Di Marco F, Vignoli A. Healthcare transition from childhood to adulthood in tuberous sclerosis complex. *Am J Med Genet C Semin Med Genet.* 2018;178:355–364.
186. Brown LW, Camfield P, Capers M, et al. The neurologist's role in supporting transition to adult health care: a consensus statement. *Neurology.* 2016;87:835–840.
187. Auvin S, Bissler JJ, Cottin V, et al. A step-wise approach for establishing a multidisciplinary team for the management of tuberous sclerosis complex: a Delphi consensus report. *Orphanet J Rare Dis.* 2019;14:91.